



## Advancing standard techniques for treatment of perianal fistula; when tissue engineering meets seton



Hojjatollah Nazari<sup>a</sup>, Zahra Ebrahim Soltani<sup>b,c</sup>, Reza Akbari Asbagh<sup>b,c,d</sup>, Amirsina Sharifi<sup>b,c</sup>, Abolfazl Badripour<sup>b,c</sup>, Asieh Heirani Tabasi<sup>b,c,d</sup>, Majid Ebrahimi Warkiani<sup>a</sup>, Mohammad Reza Keramati<sup>b,c</sup>, Behnam Behboodi<sup>b,c</sup>, Mohammad Sadegh Fazeli<sup>b,c</sup>, Amir Keshvari<sup>b,c</sup>, Mojgan Rahimi<sup>b,c</sup>, Seyed Mohsen Ahmadi Tafti<sup>b,c,\*</sup>

<sup>a</sup> School of Biomedical Engineering, University Technology Sydney, Sydney, New South Wales 2007, Australia

<sup>b</sup> Division of Colorectal Surgery, Department of Surgery, Tehran University of Medical Sciences, Keshavarz Boulevard, Tehran, Iran

<sup>c</sup> Colorectal Surgery Research Center, Imam Khomeini Hospital Complex, Tehran University of Medical Sciences, Tehran, Iran

<sup>d</sup> Research Center for Advanced Technologies in Cardiovascular Medicine, Tehran Heart Center Hospital, Tehran University of Medical Sciences, Tehran, Iran

### ARTICLE INFO

#### Keywords:

Biomaterials  
Nanotechnology  
Perianal fistula  
Tissue engineering  
Stem cells

### ABSTRACT

Tissue engineering is a promising field for treating various diseases using tissue-like structures generated through biomaterials, scaffolds, nanoparticles, biomolecules, and stem cells. This advanced method is considered one of the next-generation therapeutic techniques that may solve the therapeutic challenges in treating perianal fistula based on seton therapy. Remarkable advances in stem cell biology, genetics, biomaterials, fabrication technologies, and nanotechnology have provided the opportunity to implement this multidisciplinary approach to repair damaged tissue in the seton-based fistula treatment. In addition, tissue engineering provides us with nanostructured biomaterials to fabricate setons that can act as scaffolds, with modified mechanical and biological properties such as antibacterial and anti-inflammatory. This review focuses on the applications, advantages, and future perspectives of tissue engineering to enhance the seton placement techniques and present a novel therapeutic solution to treat perianal fistula. In addition, *in vivo* and *in vitro* studies about implementing tissue engineering in the treatment of perianal fistula are reported in this study. Also, it summarizes the surgical procedures for the treatment of fistula, including Ligation of the Intersphincteric Fistula Tract (LIFT), Fistula Laser Closure (FiLaCT<sup>TM</sup>), Over-The-Scope Clip System (OTSC), Video-assisted anal fistula treatment (VAAFT), Anal fistula plug (AFP), and Rectal advancement flap (RAF). Furthermore, the applications and properties of different setons including, cutting setons (Penrose drains, rubber band, polypropylene, and silk), non-cutting setons (loose, knot-free, Comfort, and Super Seton®), and chemical setons (Ksharasutra) are described. In the end, we present the challenges and future trends of implementing tissue engineering technology in the seton-based therapy for the treatment of perianal fistula.

### 1. Introduction

Seton placement is a well-established treatment in patients with perianal fistula that can assist drainage or closure of the fistula [1]. Various setons, including chemical, cutting, and comfort, have been developed during the past decades. However, the success rate in patients with complicated diseases, such as complex fistulas, significant tissue loss, inflammatory bowel disease (IBD), and drug resistance cases, is not desirable, compromising tissue repair in most cases [2,3]. The seton replacement method can be combined with regenerative medicine approaches, such as stem cell therapy and tissue engineering, making it a practical and innovative approach for treating perianal fistula [4]. In terms of tissue

engineering, various biocompatible scaffolds with controllable mechanical properties can be designed and fabricated for fistula healing [5,6]. Besides, it can accelerate the regeneration of damaged tissues in perianal fistulas using stem cell-based therapeutic methods [7,8]. Therefore, the expansion and development of regenerative medicine, especially tissue engineering in seton-based fistula therapy, can lead to establishing advanced multidisciplinary therapeutic methods.

A point that has not been well addressed in previous studies is the fact that morphology, structure, and biomaterial of seton need to be improved to enhance the performance of seton in fistula repair [9,10]. The concept of using seton in the perianal fistulas is a thread acting as a foreign body, exerts pressure on the sphincter, causing the sphincter

\* Corresponding author at: Division of Colorectal Surgery, Department of Surgery, Tehran University of Medical Sciences, Keshavarz Boulevard, Tehran, Iran.  
E-mail address: [smahmadit@sina.tums.ac.ir](mailto:smahmadit@sina.tums.ac.ir) (S.M.A. Tafti).

to cut off and interiorize the fistula tract gradually [11]. Seton can be categorized into cutting and draining ones, as cutting seton externalizes trans-sphincteric fistula tracts and draining seton controls sepsis within fistula tracts [12]. Hippocrates first used seton for treatment of perianal fistula with twined horsehair 400 years BC [13]. Later it became a treatment method for high fistula when simple procedure such as lay open fistulotomy was not applicable [14]. In the past decades, various types of setons, such as nylon, silk, rubber, loops, and comfort setons, have been developed and implemented to treat patients [15,16]. Recently, new materials such as silicone and nylon were used, which has only provided advantages in terms of patient comfort, but none of them changed the course of treatment and did not positively affect tissue repair [17]. Accurate diagnosis of the lesions by surgeons is the primary essential step as it dictates consequent drainage of the abscesses and placement of non-cutting setons to prevent the recurrence of abscess formation. However, setons are unlikely to be sufficient to heal the lesion, and only 20% of loos-seton-treated fistulas have been shown to improve after ten years [18]. Furthermore, this approach has a high recurrence and fecal incontinence rate as it mandates extensive surgical procedures in some cases [19]. On the other hand, cutting setons in complex perianal fistula can damage continence musculature [20].

Tissue engineering has led to progress in treating complex colorectal fistulas [21]. The goal of tissue engineering is to repair or improve the function of damaged tissue. In this approach, scaffold materials, cells, engineering methods, physiological and biochemical agents, or combinations are used to generate the target tissue [22]. In this regard, the scaffolds, patches, or matrixes designed for colorectal tissue should prevent leakage of the luminal content into the abdominal cavity, be antimicrobial, nontoxic, suturable, and biodegradable [23]. One of the critical requirements of these scaffolds is their antimicrobial property because the colorectal tract is contaminated with bacteria [24]. It has been proposed that the patches and scaffolds designed might harbor paracrine effect and induce anti-inflammatory and immune-regulatory properties with subsequent accelerated healing because of mesenchymal stem cells added [25].

It is hypothesized that materials used in scaffolds and paracrine effects of stem cells can positively interact with the tissue microenvironment to fill the damage and facilitate the induction of regeneration and healing [26–28]. To date, various methods and structures have been used to make proper scaffolds for tissue engineering, including electrospinning, microfabrication, nanoparticles (NPs), and lithography [29]. These scaffolds must have various properties to be used, including the surface characteristics to provide appropriate adhesion and proliferation of stem cells, biocompatibility, low immunogenicity, and an interconnected pore network for flow transport and cell growth [30–32]. These methods and structures for scaffold fabrication and the use of stem cells showed to be promising to improve the seton application and solve the challenges in surgery and the healing process [33]. This study aims to review the recent advancement in seton efficacy in treating perianal fistula regarding tissue engineering.

Tissue engineering can increase treatment efficiency and tissue regeneration in perianal fistulas [34]. This interdisciplinary field consists of three main elements, scaffolds, stem cells, and biological cues that can enhance seton application in different strategies. From a biomaterial point of view, scaffolds can be synthesized by nano/microfabrication techniques, with different morphologies, topographies, and mechanical properties mimicking the native tissue extracellular matrix that can be implemented as setons new generation of intelligent setons [35,36]. In addition, these engineered scaffolds can improve other properties of setons in terms of mechanical characteristics, high biocompatibility, antibacterial property, anti-inflammatory behavior, and intelligent drug delivery properties [37–39]. On the other hand, scaffolds can play as vectors to boost the proliferation of stem cells in the fistula that dramatically increase the efficacy of cell therapy, leading to increased regeneration [40,41]. Therefore, different scaffolds, stem cell sources, and biological cues can be implemented to engineer tissue-like struc-

tures for repairing different forms of perianal fistula [42,43] (graphical abstract).

This study presents an updated review of seton placement therapy in the treatment of perianal fistula. Initially, we summarized the pathophysiology of the perianal fistula and mentioned the routine surgical procedures. Next, the efficiency of the tissue engineering approach and recent reports in this area has been discussed. Finally, this combination of therapeutic methods has been argued about the challenges, advantages, suggestions, and perspectives.

## 2. Pathophysiology of perianal fistula

The term fistula determines an abnormal communication between the anorectal tract and the perineal soft tissue. Its incidence varies between 2 cases per 10,000 population per year to 9 per 100,000, and it affects men more than women, with a peak incidence between the age of 20 and 40 years [44,45]. Although fistula rarely has life-threatening consequences, it can be debilitating and socially embarrassing, significantly impacting patients' quality of life because of pain, discharge, recurrent abscess formation, sphincter, and perianal tissue destruction [46–48]. In most cases, a fistula presents de novo without any previously known disease, but it proceeds a previous anorectal abscess in about 30–50% of cases. The commonly used classification system for perianal fistula is Parks' classification which proposes four different types of perianal fistula based on the relationship between the primary fistula tract and the sphincter, including submucosal; inter-sphincteric; low trans-sphincteric (involving less than 30% of the external anal sphincter (EAS), high- transsphincteric (with more than 30% of EAS involved,) supra-sphincteric and extra-sphincteric. [49]. Simply a fistula can be categorized into simple or complex. The simple fistula is considered a Single inter-sphincteric or low trans-sphincteric tract without branching of the tract. The complex fistulas include high trans-sphincteric, supra, and extra-sphincteric fistulas, branched fistulas having multiple openings, and horseshoe fistulas (originating from the deep post-anal space extending to left and right ischio-rectal spaces) [50]. Also, low fistulas in high-risk patients at risk of incontinency (such as recurrent fistulas) are considered complex fistulas [51] patient-specific conditions such as IBD, malignancy, incontinence, chronic diarrhea, or previous irradiation can also make a fistula to be complex [18].

## 3. Advanced surgical procedures for perianal fistula

Historically, it was believed that surgical methods are the only way to treat perianal fistula. The goal of the fistula treatment is to eliminate the tract and achieve low recurrence rates while causing the least possible impact on continence. The oldest treatment applied is seton placement [12]. In endo-rectal advancement flap techniques, complete excision of the tract and the subsequent defect with a raised rectal mucomuscular flap is performed. The technique in which the fistula tract lays open is called fistulotomy [52]. The addition of marsupialization has expedited healing times in select series. During fistulectomy, complete excision of the fistula tract is done. The difference between fistulotomy and fistulectomy is the size of the wound created, which is larger in the fistulectomy procedure leading to prolonged healing time and subsequent complications of an open wound [12]. Marsupialization showed to fasten the healing process in some researches. The most common and easiest method is fistulotomy which is not recommended for complex fistula due to the high risk of recurrence, injury to the sphincter muscle, and risk of incontinence. Therefore, many surgical methods were invented to retrieve better outcomes; we mention some of the most practical and novel methods besides the seton placement in this part.

### 3.1. Ligation of the intersphincteric fistula tract (LIFT)

The ligation of the intersphincteric fistula tract (LIFT) is a newly introduced technique since 2007 for treating fistula in the anus, primarily

performed for complex or recurrent trans-sphincteric fistula [53]. The technique is implemented by secure closure of the internal and external opening of the tract and removing the infected cryptoglandular tissue. Comparing the LIFT and previously described flap procedures in the randomized trial, it has been shown more success rate and shorter time to return to work in the LIFT group while the probability of recurrence was higher in LIFT and incontinence score was not comparable between the groups [54]. Another randomized control trial study that compared LIFT and conventional open fistulotomy showed that the LIFT procedure is an effective technique with a success rate of 80%, and also LIFT had a lower rate of incontinency and shorter healing time [55]. In conclusion, the LIFT procedure had shown good potential in treating the complex perianal fistula with a satisfactory success rate (75–87.5%) and a low rate of complication, specially incontinency [55–58]. Meanwhile, the secondary success rate (80–86%) after the failure of the procedure and performing repair had shown acceptable results as well [59,60]. Also, patients with fistula associated with Crohn's disease had good outcomes after LIFT operation [61–63].

### 3.2. Fistula laser closure (FiLaC™)

Fistula Laser Closure (FiLaC™) is another modern technique with the sphincter-saving advantage, which had a satisfactory short-term and long-term success rate (64.1–81.1%) [85–89]. The procedure is applied by the closure of the internal opening and then passing the laser fiber through the catheter into the tract and delivering energy with a wavelength of 1470 nm [87]. The success rate of the FiLaC™ estimated in a meta-analysis was about 63% [90]. In the study on patients with a high risk of incontinency after fistulotomy, the healing rate was 45.6%, and healing was significant in patients with high transsphincteric fistula and age over 50 years [91]. The rate of incontinency after FiLaC™ in series with a more extensive study population ranged from 1.7 to 9.6% [85,89].

### 3.3. Over-The-Scope Clip System (OTSC)

The Over-The-Scope Clip System (OTSC) is a bear claw Nitinol clip developed for attaining hemostasis in flexible endoscopy in the gastrointestinal tract [95]. Today, OTSC has been used to treat the perianal fistula by applying it to its internal opening [96]. The success rate of the OTSC in treating complex and simple perianal fistula had been reported to be between 60 and 93.3% [97–102]. Comparing OTSC to the standard fistulectomy, a higher success rate has been shown in the OTSC group. Also, the mean postoperative stay and healing time was 1.3 and 3.2 days, respectively, shorter than the standard fistulectomy group [97].

### 3.4. Video-assisted anal fistula treatment (VAAFT)

Video-assisted anal fistula treatment (VAAFT) is a novel sphincter-saving method to treat complex anal fistula [105]. Zhang et al. assessed the efficacy of combination VAAFT with anal fistula plug and showed satisfactory results. The mean wound healing time was 46 days, and none of the patients had anal sphincter function impairment [106]. The other study that compared the VAAFT technique with fistulotomy plus seton placement had shown satisfactory results in both procedures. However, the VAAFT group had a significantly shorter healing time and minor post-operative Wexner incontinence score than the other group [107]. The success rate of VAAFT had been reported in previous studies to be around 71.2–87.1% [108–115] in complex anal fistula and 82–84% in Crohn's associate anal fistula [116,117].

### 3.5. Anal fistula plug (AFP)

Anal fistula plug (AFP) was characterized as a sphincter-preserving method trying to close the opening of the fistula [129] primarily. The

treatment period's simplicity, minimally invasiveness, and relative transience are well established [129,130]. The technique is mainly reckoned with inserting either the biologic or synthetic plug into the internal opening of the fistula tract with a suture attached to its tail [131,132]. Previous long-term follow-ups have demonstrated that the healing rate of this method varies from 54 to 80%, inversely proportional to the duration of the follow-up that ranges from 8 weeks to 6.5 months [133,134]. Moreover, Nasseri et al. have reviewed 12 follow-up studies, including 84 patients with Crohn's disease with perianal fistula regarding their major outcomes. They concluded that the fistula plug is considered a safe method with a low risk of incontinency and morbidity. The mean healing rate was about 60%, while the recurrence rate was reported to be 13.6% [135]. In addition to the biologic plug, a delayed absorbable synthetic plug was also evaluated regarding its efficacy and safety. Narang et al. have reviewed 187 patients who underwent treatment with GORE® BIO-A®, and results indicated that the healing rate was varying from 15.8 to 72.7%, with the follow-up ranging between 2 and 19 months [136].

### 3.6. Rectal advancement flap (RAF)

The rectal advancement flap (RAF) is a sphincter-preserving technique with a 66–87% healing rate. It has been suggested that it could be an optimal technique for healing complex cryptoglandular perianal fistula [137]. The transanal approach is commonly applied to lift the rectal flap and, consequently, advance distally without disturbing the sphincter [138]. Soltani and Kaiser reviewed 1654 patients either with Crohn's disease or cryptoglandular anorectal fistula who had gone through RAF. They assessed the healing/incontinency rate, and it was 80.8 /13.2% and 64/9.4% for Crohn's disease and cryptoglandular anorectal fistula, respectively [139]. In addition, it has been proposed that the mean recurrence rate for patients with Crohn's disease who have anorectal fistula undergoing RAF is around 30% [140]. However, it has been noted that although healing and recurrence rates of LIFT and RAF procedures among patients with cryptoglandular or Crohn's disease fistula are likely similar, the incontinency rate could be higher in RAF follow-ups [45]. The introduction of new compatible materials could bring up new results regarding efficacy, recurrence, and incontinency risk. It has been revealed that RAF in comparison to Permacol collagen paste had higher healing rate and against porcine collagen paste, it showed significantly lower incontinency rate [141]. It is worth noting that proximal superficial cauterization, emptying regularly fistula tracts and curettage of tracts (PERFACT) procedure is also known as one of the novel procedures for complex anorectal fistula targeting both the internal opening and tract of the fistula. It has been reported that the healing rate of the PERFACT procedure is about 80% while its recurrence rate is 20% [142,143].

Multi-dimensional analysis incorporating the methods mentioned above would help to clarify the true efficacy of different techniques. Lin et al. provided a well-discussed comparison between RAF and AFP procedures, including long-term follow-ups. They could illustrate that RAF is the choice of treatment in the matter of healing and recurrence rates. Still, regarding complications of the fistula treatment during follow-ups, there is no significant difference found. It was carried out that RAF might appear a more creditable choice for treating complex cryptoglandular fistula while AFP is less invasive and more comfortable [144]. Additionally, it has been recorded that RAF could be accompanied by less recurrence and complication rates than seton placement in this group of patients [145].

## 4. Seton placement techniques for treatment of perianal fistula

Hippocrates described the use of horsehair wrapped around a lint thread as a seton to treat fistula for the first time [146]. Setons are generally a looped shape material passing through the external opening to the fistula tract and then internal opening to facilitate abscess drainage

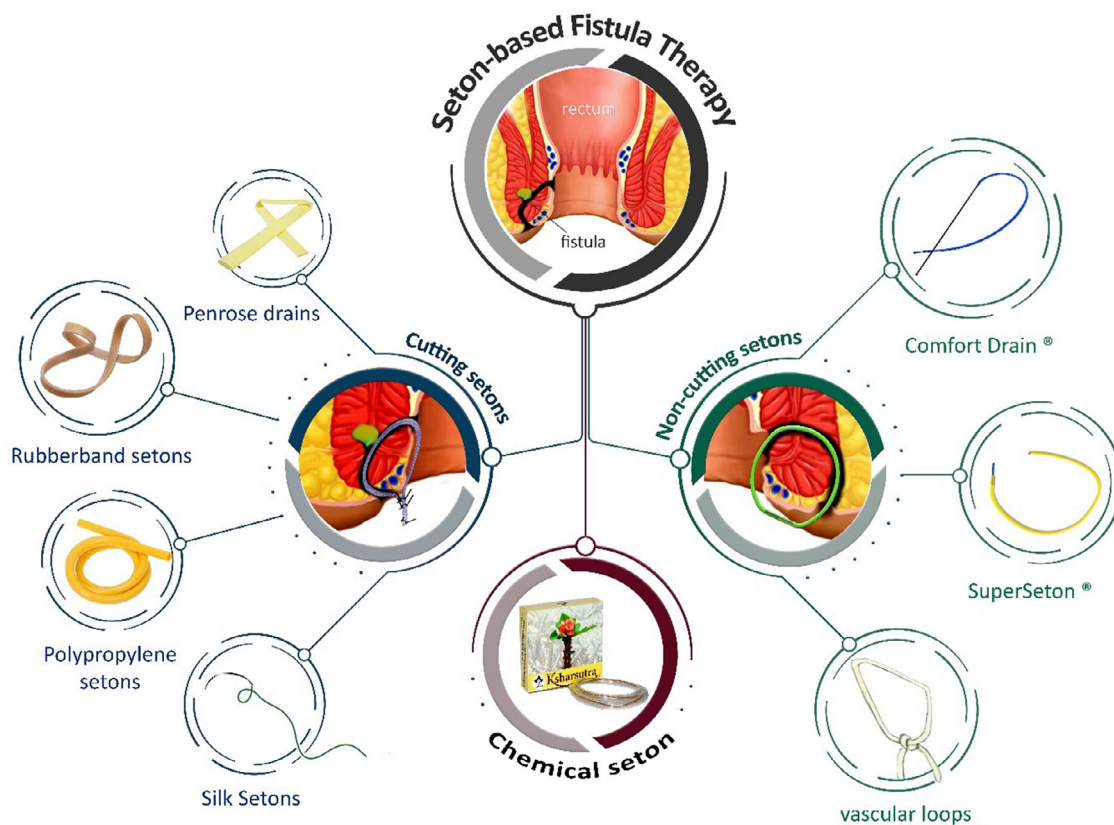


Fig. 1. Seton-based therapy for the treatment of perianal fistula. The setons are categorized into cutting, non-cutting and chemical setons.

and provide a local inflammatory reaction with subsequent granulation formation and fibrosis [147]. Setons are usually the first treatment for perianal fistula as it allows the drainage of the fistula tract and accompanying abscess [148]. Antibiotics, mainly metronidazole or ciprofloxacin, may be supplemented, which further promotes healing [15]. Different materials have been used as setons, including silk, wire, elastic bands, a Penrose drain, and nylon [10]. Setons can be categorized into cutting, non-cutting, loose and chemical ones, separately discussed in the following (Fig. 1). Generally, seton might seem harmless at first, but it should be used with caution by those surgeons who have a vast knowledge of perianal anatomy to preserve a better quality of life after fistula healing.

#### 4.1. Cutting setons

The cutting seton is any surgical thread used to cut through the tissue, either by mechanical or chemical means [45]. A seton placement is the preferred treatment option when there is a considerable bulk of sphincter involved in the anal fistula. Cutting seton placement is a commonly used technique by many surgeons [149]; it gradually cuts through the sphincters, so it causes minor damage to the sphincters than lay open fistulotomy [46]. The suture or band is passed along the tract and tied firmly around the sphincter muscles [12]. The seton is usually tightened every 1 or 2 weeks, and it is continued until it completely cuts through. Alternatively, for shorter periods of treatment, a two-staged fistulotomy can be performed [150]. In this method, a seton is placed for 6 to 8 weeks followed by a fistulotomy [151], but there is a higher risk of incontinence, especially with multiple tracts [152].

The advantages of cutting seton in high perianal fistulas are good efficacy in eradicating fistula and low recurrence rate [153–157]. When we compare the results with mucosal advancement flap, the success rate is considerable, although the time for healing might be longer and more surgeries are demanded [158–160]. The results for the LIFT procedure are similar, with about 40% primary success rate and 75% subsequently

[161]. It should also be noted that in cases of previous multiple surgeries, these techniques could be challenging and complicating the patient's current situation [162]. In these situations, seton drainage might be the most reasonable option. The advantage of this method is the ability to drain the fistula, which prevents recurrent abscess [10]. In addition, the fibrosis made around the seton during the slow division of the sphincter prevents retraction of the sphincter.

Incontinence rate for cutting setons has been reported to range from 3.2 to 30%, with an average rate of 12% [163,164]; Due to higher rate of incontinence with high-trans-sphincteric and supra-sphincteric fistulas, some authors suggest that cutting seton is a suitable for low trans-sphincteric fistulas in which the degree of incontinence is acceptable (causing gas or minor stool incontinence) [165]. The recurrence rate of fistulas treated with cutting seton has been reported from 5% to 29%, but usually less than 10% of cases [149,151,166–168]. The variation in results might be due to different fistulas anatomy, history of previous operations, follow-up intervals, and factors interfering with healing.

Incontinence is one of the catastrophic complications of using setons; thus, preserving the anal sphincter function is mandatory. Previous reports on the incontinence rate after the application of setons are controversial. Mentis et al. [169] reported a healing rate of 45% at 1-month post-surgery and 100% by three months. The same result about healing was reported by Akhtar et al. [170]; within three months, these two studies did not report post-operative development of incontinence. In contrast to these studies, Zhang [171] reported high incontinence rates after using cutting setons. Also, the same result was revealed by Hämäläinen et al. [172]; they reported a recurrence rate of 6% and the rate of minor impairment symptoms in anal control to be 63%. In light of the results provided by these studies, it is too immature to conclude that routine use of setons for all high fistulas is secure.

A systematic literature review consisted of 18 studies showed that the recurrence rate would be 5% if the patients undergo preservation techniques of the internal anal sphincter and 3% if the surgical divi-

sion of the internal anal sphincter is performed. They also proposed an overall fecal incontinence rate of 5.6% and 25.2% in the preservation and division group [167]. In conclusion, it can be stated that there is no difference in incontinence rates between the cutting seton and fistulotomy for low superficial fistulas with short tracts. In cases presented with acute perianal abscess, fistulas are not usually treated at the time of surgical drainage, but they can be postponed until the abscess is completed to evaluate fistula anatomy accurately. Patients who complain of major incontinence should not undergo cutting seton placement. The cutting seton would be for complex fistula in the anus, but female patients and those with previous perianal surgery might be considered for non-cutting setons.

Cariati et al. set a series of indications for evaluating the efficacy of performing fistulotomy and seton insertion [162]. They believe complete fistulotomy is superior for subcutaneous, low inter-sphincteric, or very low trans-sphincteric fistula (less than 10% of external sphincter involvement). On the other hand, cutting seton insertion (with partial fistulectomy or partial fistulotomy) without cutting the external and the internal anal sphincter is a suitable treatment for trans-sphincteric fistula (with more than 10% of sphincter involvement). They have claimed that these indications helped reducing up to 20% sphincter cutting procedures. In this study, the authors concluded that the healing rate, transient fecal soiling, and recurrence were 100%, 11.5%, and 6.5%, respectively. Different materials have been used as cutting seton; steel wires were used as cutting seton in the previous decade [173,174], but they have lost popularity nowadays. In the following, different kinds of setons for the treatment of perianal fistula are briefly presented.

#### 4.1.1. Penrose drains

Penrose drains were also used as seton most frequently in horseshoe fistulas and in the presence of posterior ischio-rectal abscess simultaneously for drainage of deep postanal space [175]. It is a flexible rubber or silicone tube which allows fluids to drain effortlessly by gravity. Using the Penrose drain was published in 1984 for the first time, which revealed a good result in 20 patients with complex anal fistula [176]. It has also been used as a cutting seton by cutting the enclosed sphincter muscle with pressure necrosis [110,176]. Challenges in applying this type of drainage have limited its use as passing it through the small lumen, fibrotic fistulas in chronic cases are complicated, and attaching it to the probe is impossible in some cases. Stripes of the surgical glove are also a substitute that has the same tackles as Penrose drains, and the appliance is similar [177–179].

#### 4.1.2. Rubber band setons

The rubber band seton was mentioned as a treatment method for anal fistula for the first time in 1966. It was used for treating patients with deep anterior space- abscess/anal fistula and chronic perianal fistula [180]. A previous study that compared the rubber band seton with echeleon suture has shown complete healing in all patients after three months in both groups and recurrence rate of 7.5% and 2.5%, respectively [15]. Also, rubber seton was mentioned as a cheap, acceptable treatment with less pain score for treating perianal fistula [15,181]. Also, comparing the rubber seton with nylon ligation had revealed a practical function, reduced hospital stay and complication, and good drainage in patients with extra-sphincteric and trans-sphincteric fistulas [181].

#### 4.1.3. Polypropylene setons

Polypropylene or prolene is a thermoplastic polymer with good resistance to chemical reactions, which is a proper candidate for treating perianal fistula. This nonabsorbable monofilament thread is also used as a seton in some centers, but patients were not satisfied with the material and the knot, so it is not much popular [154,182]. Comparing silk and polypropylene seton has shown shorter recovery time and more pain score in the polypropylene group, while no difference was seen in the recurrence and incontinency between these two groups [183]. Also, local infection requiring fistulotomy after seton placement was higher in

silk seton, however pain score was higher in the polypropylene group [17]. An animal study in the rat model of the anal fistula compared fistulotomy, polypropylene, and polydioxanone wire. It revealed that there was no difference in the degree of fibrosis made among these three groups. Researchers were unable to suggest any of these wires be superior to fistulotomy [184].

#### 4.1.5. Silk setons

Silk suture is a nonabsorbable material that is one of the most common setons used worldwide [185–187]; it is known that bacterial colonization can occur in silk material; thus, it has not been recommended for contaminated environments [188] or prolonged periods [189]. Silk sutures can be used as cutting [157] or non-cutting seton [190], with healing rates of 96% [157] and 75% [190], respectively. The recurrence rate in previous studies using silk seton was about 2.4–9.8%, and the incontinence rate to flatus was 8–15.7%, and to fecal was none [10,157,182,190].

#### 4.1.5. Polyester setons

Polyester sutures or ETHIBOND EXCEL® is a nonabsorbable material composed of polyethylene terephthalate that can be applied as seton. Polyester sutures are reported to cause less inflammation than monofilament polypropylene sutures and less discomfort [130]; therefore, it can be suitable, especially in inflammatory conditions such as Crohn's disease perianal sepsis or long-term use [191,192].

#### 4.2. Loose setons

Loose seton is another type of seton when the thread or band is passed through the tract, and a loop is formed and tied around the sphincter without any tension [193]. This method does not induce the constant perianal pain caused by the cutting seton and prevents injury to the sphincters [194]. The disadvantageous point of application of loose seton is the extended period of healing time as it slowly drains and palliates the fistula tract [163,195]. Thus the indwelling "long-term seton" is meant to prevent abscess formation and perianal sepsis in chronic cases. In contrast, some surgeons assume that the loose seton can cut through the tissue in a timely fashion and preserve the sphincter; thus, they advise using it instead of cutting setons to avoid complications [195]. Some surgeons instruct the patients to pull the thread daily to accelerate the granulation process, though the amount of pressure and the level of compliance cannot be determined, and most patients reported this approach to be painful and dissatisfying [196]. Nonetheless, when the surgeon is concerned about the patient's continence, for instance, in complex fistulas where multiple operations were performed or in inflammation at the fistula site such as Crohn's disease, a loose seton is always preferred [197–199].

#### 4.3. Knot-free setons

Knot-free or knot-less setons are a piece of tubular-shaped polypropylene or silicon material designed to insert the fistula tract and hook the two ends. SuperSeton (MediShield B.V., Amsterdam, The Netherlands) and Comfort Drain (AMI, Feldkirch, Austria) are two commercially available knot-free devices used to treat perianal fistula. There are also knotless setons made such as super seton (MediShield B.V. Amsterdam) or Comfort seton (AMI, Feldkirch, Austria), which cause fewer symptoms than the regular knotted vascular loops for the patients [16]. In a study by Kristo et al., they applied the Comfort Drain system and reported enhanced physical and mental health along with less burning sensation and pruritis [200]. Furthermore, Stellingwerf et al. used the Comfort Drain and stated that this type of knotless setons falls out easily, and the whole system has a secure hook as applicator, which comes with the knotless seton and provides much stability than the other system and prevents buckling during placement [146]. Thus it is easily

applied, and the procedure will end in the median of 21 min. These systems are relatively new, and a large randomized clinical trial is not yet performed, so a definite conclusion on their effect and recurrence rate besides incontinency rate is unclear.

#### 4.4. Vascular loops

Silastic vascular loops are used as setons causing less pain and discomfort [201]; its good biocompatibility makes it a good material for wound dressing [202,203]. It has also been used as a cutting seton [156,204], but a major problem with silicone is the tissue reaction caused by the released particles that form a fibrous capsule around it [205,206]. This process might impair the healing and prevent the seton from cutting through the sphincters. Altogether, vascular loops are a good option for drainage setons, especially if long-term seton is needed. Cable ties were also used as cutting seton in a few studies [147,207], but since the material is not approved for medical use and post-operative pain might be severe, it seems unacceptable for routine practice.

#### 4.5. Chemical seton

Chemical seton is a type of seton that can chemically react with the surrounding tissue and chemically debride the surrounding tissue [208]. The most popular type of these setons is Ksharasutra. Ksharasutra (Kshara sutra) is a cotton thread coated with Ayurvedic medicine [209]. The chemical substance, an alkaline, can make good cauterization of the fistula tract [210]. A study using the commercial Ksharasutra in India showed no difference in healing time compared to fistulotomy [211]. Another study reported that Ksharasutra seton needed more healing days than the fistulotomy group [212]. Possible complications can be allergic reactions to the chemical substance, abscess formation, burning sensation, especially in the first few days after the operation, bleeding and, wound discharge [211]. Unfortunately, none of the studies available compared chemical setons with non-chemical setons, and its efficacy on high perianal fistulas cannot be evaluated.

### 5. Tissue engineering assisted setons

In the last decade, the benefits of advanced regenerative medicine, such as tissue engineering and stem cell therapy, provide clinicians in colorectal surgery with novel and highly efficient techniques for treating perianal fistula in patients with underlying diseases such as Crohn's and other IBDs [25,213,214]. Tissue engineering exploits stem cells [215], scaffolds [216], and signaling molecules [217] in various ways to maintain, heal, restore and enhance the functionality of damaged tissues, including unwelcomed tract caused by anal fistula. This interdisciplinary approach that combines advanced technologies, including nanotechnology [218], micro/nanofabrication techniques [219], biomaterials [220], and molecular medicine [221], can enhance the efficacy of seton-based therapeutic techniques for healing fistula.

Bacterial infections that are the impartible disturbing elements in treating perianal fistula can be eliminated via antibacterial setons [222,223]. Antibacterial agents, including conventional antibiotics, metallic nanoparticles such as silver [224], zinc [97], and copper [225], and polymers with natural antibacterial properties such as chitosan [226], can be incorporated into the structure of setons. In 2008, Blaker et al. fabricated porous spherical microscale scaffolds using Poly (D, L-lactide-co-glycolide) and silver-doped phosphate glass by thermally induced phase separation method. Their study showed that these degradable antibacterial scaffolds could release silver ions leading to counter the colonization of bacteria playing a role in perianal fistula in rodent wound model [227] (Fig. 2a). Recent studies showed that incorporating silver nanoparticles into scaffolds can significantly improve their antibacterial, antiviral, and mechanical properties [228]. The releasing of silver ions via these NPs can endanger the viability of bacterial elements [229]. Therefore, these NPs attracted much attention in wound healing

and bone regeneration, where infections are considered to significantly delay therapeutic approaches. Studies revealed that silver NPs have a strong anti-inflammatory effect in chronic digestive diseases such as colitis [230]. Besides, Zhang et al. showed that silver NPs-coated sutures increase their antibacterial and mechanical properties, significantly reduce inflammation, and improve intestinal anastomosis healing in mice [231]. Incorporating antibacterial NPs in setons' structure can significantly improve their efficacy in treating perianal fistula in IBD patients.

The extraction of the setons out of the fistula tract during the treatment period can sometimes be challenging, as they might get trapped in the tract. However, it can be solved by presenting biodegradable setons manufactured using tissue engineering methods [232]. The setons can be fabricated using various degradable polymers with good mechanical properties. Besides, the degradation rate of setons can be optimized for different fistula types [233]. In the early studies, as biodegradable polymers, polyglycolic acid and trimethylene carbonate demonstrated an influential role in treating anal fistula [234,235]. Pramadiati loaded Polyphenol, as an immunosuppressive drug, into poly(DL-lactide-co-glycolide) acid (PLGA) films as biodegradable seton [236]. In the context of anal fistula, it is more beneficial to use a degradable structure to prevent the formation of a foreign body granulomatous reaction.

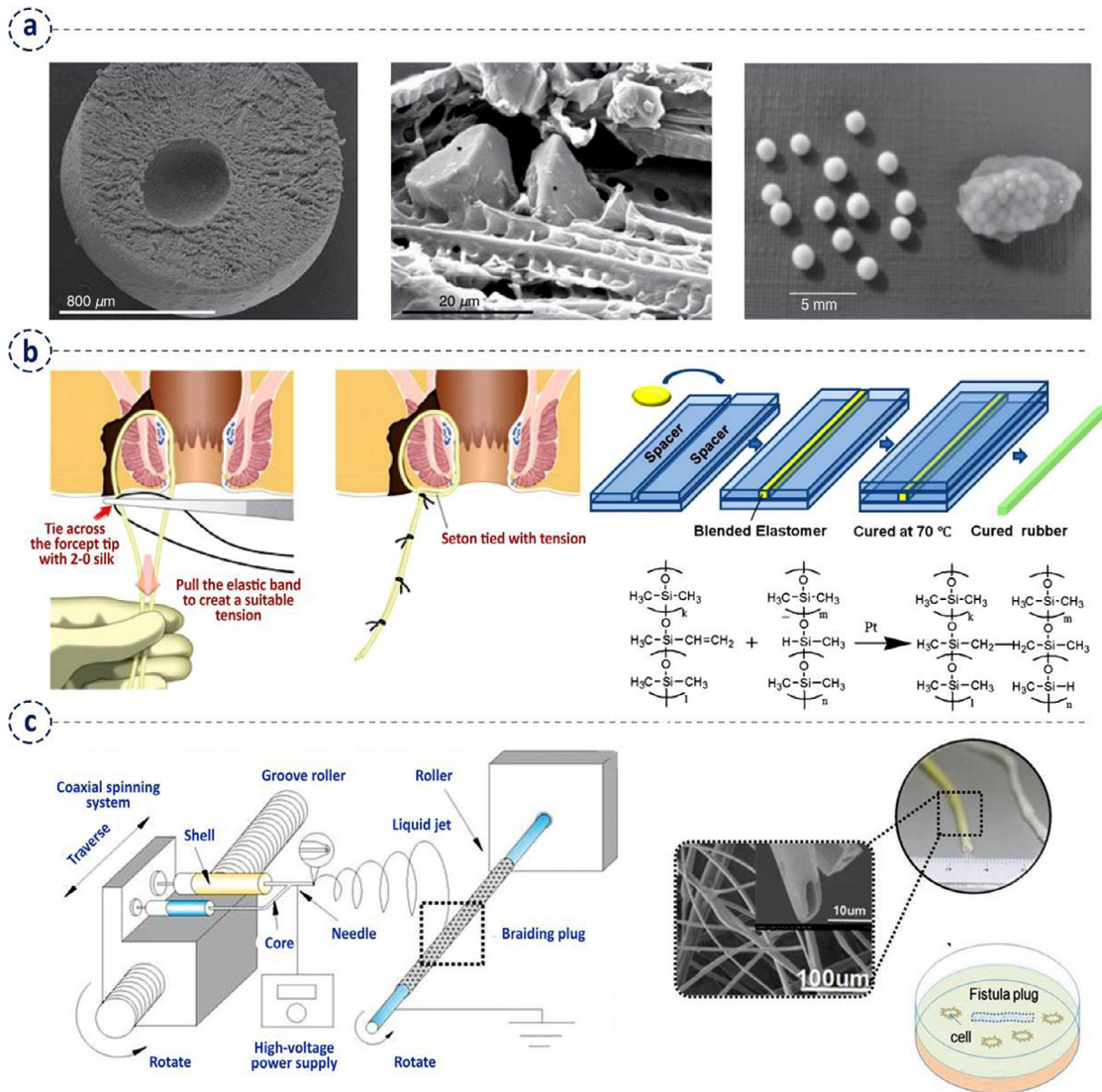
Furthermore, the injection has the effect of mechanically filling the defects; then, a transition matrix is formed at the injection site. Regarding the advantages of injectable polymers, Maternini et al. provided non-cross-linked equine collagen injectable polymers (Salvecoll-E® gel) to treat anal fistula. They demonstrated that Salvecoll-E® gel is a promising technique for treating anal fistulas, and it is well tolerated by the patients [232].

Various drugs, antibiotics, and antibacterial agents can be encapsulated inside polymers for obtaining a slow release profile and uniform healing of the fistula. In the beginning studies, Li et al. incorporated lidocaine into silicone bands setons in the surgical management of anal fistula and provide a painkilling effect for patients during the treatment [237] (Fig. 2b). In another study, Xie et al. demonstrated that simultaneous encapsulation of curcumin, an anti-inflammatory agent, and 5-aminosalicylic acid into silk fibroin membranes via electrospinning increased the proliferation of fibroblast. The electrospinning method did not change the chemical structure and efficacy of encapsulated drugs and make the steady release of drugs possible [238] (Fig. 2c). Interesting results from recent studies indicated that anti-TNF drugs in IBD treatment, such as infliximab and adalimumab, can be incorporated into the network of hydrogels and scaffolds [239]. For instance, Zhao et al. loaded infliximab and cells into a hyaluronic acid-hydrazide composite hydrogel to treat rheumatoid arthritis in the critical-sized bone defect rabbit model [240,241]. The accompanying setons with such Anti-TNF drugs can significantly enhance treatment efficacy in patients, especially with an IBD.

In recent years, a new generation of biomaterials called smart biomaterials has attracted much attention in drug delivery and regenerative medicine [242,243]. These polymers are categorized into responsive, self-healing, and shape memory polymers and have several applications in fabricating scaffold, 3D bioprinting, artificial muscles, surgical sutures, and devices. These materials can significantly improve the efficacy of setons via their unique properties. Scaffolds and nano drugs fabricated using these materials respond to environmental stimuli, such as pH, temperature, biological cues, and chemical agents in the injured environments such as fistula. Various smart scaffolds, including smart self-contracting hydrogels [244], antibacterial injectable self-healing wound dressers [245], and moisture-responsive shape memory [246] biomaterials, have been developed for wound healing applications. Different micro/nanostructures with various morphologies and scales can be fabricated using a specific category of smart materials, shape memory polymers through the four-dimensional (4D) bio/printing technique [247]. These structures can be injected into the wounds to expand and transform into different 3D shapes in response to different stimulates leading to refill the injured tissues and tracts [42,43].

**Table 1**  
The applications of the LIFT procedure for the treatment of perianal fistula.

Author[Refs.]	year	method	No of patients	Success rate	complication	recurrence	Healing time (days)	Follow up (month)	Type of fistula
Madbouly et al. [64]	2021	LIFT	49	65.30%	-	9.5%	21.6 ± 5.4	12	High trans-sphincteric anal fistulas
		LIFT+PRP	49	85.71%	-	9.3%	15.7 ± 4		
Sebai et al. [55]	2021	LIFT	15	80%	0	-	4.53w	6	low transsphincteric perianal fistula
		conventional fistulotomy	15	93.3%	13.3%	-	5.67 w		
Praag et al. [65]	2021	LIFT	12	100%	0	0	-	2-6	perianal fistulas in Crohn's disease
Celayir et al. [66]	2020	modified LIFT	56	87.5%	-	-	-	-	high transsphincteric fistula, high intersphincteric fistula, and horseshoe abscess
Eray and Rencuzogullari [67]	2020	LIFT	42	57.1%	-	-	-	15-36	high trans-sphincteric, horseshoe fistula, and supra-sphincteric
Wu et al. [68]	2020	video-assisted modified LIFT	30	-	-	-	-	-	Parks type II anal fistula
		LIFT	40	55%	-	41%	-	-	Complex Anal Fistula
Hoof et al. [70]	2020	LIFT	-	84%	-	-	-	7	anal fistulas
Wanitsuwan et al. [71]	2020	video-assisted modified LIFT	103	84.5%	0	-	4 w	15-38	anterior high transsphincteric fistula, semi-horseshoe fistula, and horseshoe fistula
		LIFT	45 45	-	-	-	-	-	Anal fistula
Tsang et al. [56]	2020	LIFT BioLIFT	48 10	87.5%	-	12.5%	-	-	Complex Anal Fistula
		LIFT	40	80%	-	0	-	-	-
Ram et al. [73]	2020	a simplification of LIFT	47	80.9%	-	-	-	12	cryptoglandular anal fistula
Mujukian et al. [63]	2020	[63] <sup>b</sup> advancement flap	38 22	46%	-	-	-	6-192	Complex anal fistula in Crohn's disease
		LIFT BioLIFT	75 44	50%	-	-	-	-	-
Zwiep et al. [74]	2020	LIFT BioLIFT	75 44	58.7%	17.3%	-	-	7	Anal fistula
Praag et al. [62]	2020	LIFT	19 21	75.0%	22.7%	-	-	2	-
		advancement flap	19 21	89.5%	15.8%	21.1%	-	-	-
Lau et al. [59]	2020	LIFT BioLIFT	105 11	62.9%>80.0%	-	anteriorly located fistula	-	-	Trans-sphincteric perianal fistula.
		LIFT	28	34.9%>81.9%	-	14.2%	-	6	Anal fistula
Cianci et al. [75]	2019	LIFT	28	85.7%	-	20%	-	12	high transsphincteric fistula
Göttgens et al. [76]	2019	LIFT	46	37%	-	-	-	24	perianal fistula
Mijnsbrugge et al. [77]	2019	LIFT	45	40%	0	-	-	5-18	transsphincteric fistulae
Osterkamp et al. [60]	2019	LIFT	65	42%>86%	-	67%	-	16-47	trans-sphincteric perianal fistula
Zhao et al. [78]	2019	LIFT+plug	78	96.2%	12.82%	2.5%	16 d	4.5-68	high transsphincteric fistulas
Sun et al. [79]	2019	LIFT	70	81.7%	2.8%	15.7%	-	12-51	complex fistula-in-ano
Wen et al. [57]	2018	LIFT	62	83.9%	0	-	-	8-27	Simple and complex transsphincteric fistulas
Kang et al. [58]	2018	LIFT	28	75%	0	18%	4 w	3-14	transsphincteric fistulas
Araújo et al. [80]	2017	LIFT	38	79%	-	-	-	71	Trans-sphincteric intersphincteric, high trans-sphincteric semi-horseshoe, and horseshoe fistulas
Malakorn et al. [81]	2017	LIFT	251	87.65%	0	-	-	-	complex cryptoglandular anal fistula
Galán et al. [82]	2017	LIFT	55	70%	0	12,7% posterior location and complexity of the tract	4-8 w	-	-
Kamiński et al. [61]	2017	LIFT	23	48%	-	-	-	31	trans-sphincteric Crohn's fistula tracts
Xu and Tang [83]	2017	LIFT	55	60%	10.9%	40%	-	16	recurrent anal fistula
Chen et al. [84]	2017	LIFT	43	83.7%	9.3%	-	-	13-63	uncomplicated transsphincteric fistulas horseshoe transsphincteric fistulas, multiple fistulas



**Fig. 2.** (a) Fabricating antimicrobial microspheres as for repairing tissues in perianal fistulae. The scanning electron microscopy (SEM) images of phosphate glass containing microsphere (left and middle). The implementation of antibacterial glass particles within the polymer (right), reprinted from [227] with permission from Wiley Online Library. (b) Illustration of implementing and fabricating elastic band silicone setons to treat anal fistula, reprinted from [237] with permission from Springer. (c) The illustration of the modified electrospinning machine for fabricating silk fibroin-based anal fistula drug-loaded anti-inflammatory plugs to treat perianal fistula, reprinted from [238] with permission from Wiley Online Library.

**Table 2**  
The applications of FiLaC™ for treatment of perianal fistula.

Author [Refs.]	year	No of patients	Success rate	complication	recurrence	Healing time (days)	Follow up (month)	Type of fistula
Wolicki et al. [89]	2021	83	74.7%	9.6%	-	-	13-84	transsphincteric and intersphincteric anal fistula
Brabender et al. [92]	2020	18	22%	0	-	-	18-46	fistula-in-ano
Serin et al. [93]	2020	35	42.9%	9%	-	-	6-17.6	perianal fistula
Alam et al. [94]	2020	20	55%	-	-	-	2-22.5	Crohn's anal fistula
Marref et al. [91]	2019	69	45.6%	0	-	-	4.2-9.3	High transsphincteric anal fistula
Wilhelm et al. [85]	2017	117	64.1%	1.7%	-	-	6-60	cryptoglandular fistulae Crohn's fistulae
Giamundo et al. [86]	2015	45	71.1%	0	-	35	6-46	anal fistulas
Giamundo et al. [88]	2014	35	71.4%	0	5.7%	-	3-36	trans-sphincteric anal fistula
Wilhelm [87]	2011	11	81.8%	9.09%	-	-	-	cryptoglandular anal fistula



**Table 3**  
The applications of OTSC for treatment of perianal fistula.

Author [Refs.]	year	method	No of patients	Success rate	complication	recurrence	Healing time (days)	Follow up (month)	Type of fistula
Grossberg et al. [103]	2020	OTSC	19	66.7% 38.5%	-	-	-	2-10	simple and complex fistulas
Marinello et al. [102]	2018	OTSC	10	60%	0	30%	-	6-26	simple and complex fistulae cryptoglandular and stable Crohn's disease fistulae
Mascagni et al. [97]	2018	OTSC standard fistulectomy	15 15	93.3%	-	-	-	-	anorectal low trans-sphincter fistula
Prosst and Joos [99]	2016	OTSC	96	79%	-	-	-	6	Complex anorectal fistulas. inflammatory bowel disease
Dubois et al. [104]	2015	OTSC rectal mucosa advancement flap	46 46	-	-	-	-	12	complex anal fistulas
Mennigen et al. [98]	2015	OTSC	10	70%	-	30%	72	5-17	cryptoglandular and one Crohn's disease-associated fistula
Prosst et al. [100]	2015	OTSC	20	90%	-	-	-	6	ryptoglandular anorectal fistula
Prosst et al. [101]	2013	OTSC	10	90%	-	-	-	6	transsphincteric and suprasphincteric fistulas

In fistula treatment via tissue engineering approaches, setons find a new definition and act as scaffolds for the proliferation and differentiation of implanted stem cells in the fistula tract [234]. These scaffolds can be derived from a variety of natural or synthetic materials and are intended to simulate the natural three-dimensional (3D) microenvironments, architecture, extracellular matrix (ECM) [248], nanotopography [249], and other properties of target tissue [250]. These biocompatible scaffolds can be fabricated with controllable properties such as permeability, degradation rate, and architecture [251]. A variety of stem cells, such as mesenchymal stem cells (MSCs) and embryonic stem cells, can be cultured on the surface of setons or plugs or encapsulated inside their structure to support cell shortage in the fistula tract and accelerate the healing process. Recently, Dozois et al. introduced adipose-derived MSCs coated plug to treat patients with trans-sphincteric cryptoglandular fistulas. Their study showed that the MSCs coated plug could be used as safe and feasible devices to treat anal fistula [234].

Regarding these results, the application of setons as the scaffolds for the proliferation of implanted stem cells in the fistula tract can be considered a promising method for treating fistula. In the last years, the MSCs have been implemented for stem cell-based therapy of Crohn's disease patients with perianal and rectovaginal fistula [252]. The application of MSCs for the perianal fistula is mainly based on the immunomodulatory and anti-inflammatory features [253]. Despite growing attention to the application of MSCs to treat anal fistula, there is still no well-established standard method for MSCs transplantation. Regarding these arguments, there are various methods for the preparation of the fistula tract for cellular infusion. The recent studies demonstrated that the initial placement of setons before cell infusion is safe and effective in closing external openings [235,254–257].

## 6. Discussion, challenges, and future trends

Traditional treatments for perianal fistula are fistulotomy and seton placement as an immediate or delayed way to gradually transect the sphincter muscle complex [163]. Setons are commonly applied to treat high or complex fistula, and their function is to provide drainage along with induction of chronic fibrosis [185]. Using setons to treat a complex anal fistula is an affordable and straightforward method that most patients can tolerate [20]. However, this method takes a long time to reach substantial healing, and the rate of fecal incontinence is considerable. Enriching seton-based therapeutic methods with regenerative medicine approaches such as tissue engineering and stem cell-based therapies can

preserve the health of sphincter muscle and minimize the side effects such as the risk of fecal incontinence while decreasing the time of fistula healing [20]. In addition, the mechanical properties, biocompatibility, and degradation rate of setons as engineered scaffolds can be enhanced through advanced fabrication methods [258,259]. Besides, this generation of setons can be a vector for stem cells and carry different drugs, growth factors, and antibacterial and anti-inflammation agents [227,231,238]. However, there are limited studies in this area, and serious challenges should be addressed.

A limited number of biomaterials have been implemented on setons, and studies that used this type of setons to treat perianal fistula are scarce [236,238]. On the other hand, the mechanical properties of scaffold seton, either cutting or non-cutting, have not yet been studied enough. The designed scaffolds for perianal fistula healing and regeneration should have specific mechanical properties. For instance, they should be elastic, flexible, and knot-able and be formed into small-sized tubes [181,260]. Also, their degradation rate and drug-releasing ability should be addressed compatible with the type and size of the fistula. In terms of fabric source, the biomaterials can have a natural, synthetic, or hybrid origin regarding Food and Drug Administration (FDA) approved materials.

In terms of regenerating damaged tissues, the scaffolds need to mimic the microenvironment of tissues involved in fistula and load cells and biomolecules necessary for tissue formation and wound healing [261,262]. In addition, the incorporating of growth factors, anti-inflammatory agents, drugs, and antibiotics can significantly increase regeneration [263,264]. Each agent's release profile and possible cytotoxicity is a big challenge that should be investigated for each disease. Incorporating setons with immune regulators, such as exosomes, can be beneficial [265]. A variety of stem cells, such as MSCs, human induced pluripotent stem cells (hiPSCs), and embryonic stem cells (ESCs), can be seeded on the surface of scaffolds or incorporated into scaffolds [266]. The paracrine effect of stem cells can significantly improve the healing of damaged tissue [267]. Therefore, the source of cells, population, and density of stem cells should be considered as an important parameter in this case [213]. The viability of stem cells inside cell-laden setons is another crucial factor that microfabrication systems can address [268].

Developing setons as scaffolds for perianal fistula tissue engineering is a multidisciplinary area requiring a high level of collaboration between surgeons, stem cell scientists, biomaterial engineers, and the clinical team. This promising technique can be widely utilized in the clinics if challenges in supplying a high population of the good manufactur-

**Table 4**  
The applications of VAAFT for treatment of perianal fistula.

Author [Refs.]	year	method	No of patients	Success rate	complication	recurrence	Healing time (days)	Follow up (month)	Type of fistula
Zhang et al. [106]	2021	VAAFT AFP	57	89.47%	0	10.52%	46	28	complex anal fistulae
Yao et al. [118]	2021	VAAFT FILAC	-	-	-	-	-	-	-
Zhang et al. [119]	2021	VAAFT AFP	26	88.46%	0	11.44%	33±10.5	6-18	horseshoe anal fistula
Zhang et al. [107]	2020	VAAFT + internal opening closure techniques / anal fistulotomy + seton placement	3738	86.5% 94.7%	-	13.5% 5.3%	27.05±6.91 34.55±4.34	6	Parks II anal fistulas
Zelić et al. [115]	2020	VAAFT	73	71.23%	0	28.76%	42	24	complex cryptoglandular anal fistulas
Regusci et al. [114]	2020	VAAFT	96	83.3%	0	16.7%	-	36	complex anorectal fistula
Torre et al. [120]	2020	VAAFT LIFT	2826	85.71% 80.76%	-	39.2% 42%	59.1 57.6	18	high trans-sphincteric anal fistula even with abscess
Lopez et al. [121]	2020	VAAFT	20	78.95%	5.26%	-	-	6	-
Giarratano et al. [113]	2020	VAAFT	72	79%	0	11%	-	32±18	complex anal fistulae
Liu et al. [112]	2020	VAAFT/ fistulotomy plus seton	6880	84.4% 85.9%	-	15.6% 14.1%	-	12	complex anal fistula
Tozer et al. [122]	2019	VAAFT + seton	-	-	-	-	-	-	-
Zheng et al. [123]	2018	VAAFT fistula resection plus seton	4245	-	2.4% 20%	7.1% 15.6%	-	6	complex anal fistula
Adegbola et al. [117]	2018	VAAFT	25	84%	0	4%	-	-	Crohn's anal fistula
Stazi et al. [111]	2018	VAAFT	224	77%	-	23%	-	27-60	complex perianal fistula
Romaniszyn and Walega [124]	2017	VAAFT	68	54.41% (73.3%- 39.47%)	0	0	-	31	simple and complex fistulas
Jiang et al. [110]	2017	VAAFT	52	84.6%	0	15.4%	-	9	complex anal fistula
Seow-En et al. [125]	2016	VAAFT	41	70.7%	-	22%	-	34	cryptoglandular anal fistulae
Liu et al. [109]	2015	VAAFT	11	72.7%	0	-	-	-	complex anal fistula
Zarin et al. [126]	2015	VAAFT	40	92.5%	0	7.5%	-	6	anal fistula
Kochhar et al. [127]	2014	VAAFT	82	84.14%	0	15.85%	-	-	fistula in ano
Wałęga et al. [128]	2014	VAAFT	18	83%	0	17%	-	10	anal fistula
Schwandner [116]	2013	VAAFT+ advancement flap repair	13	82%	0	-	-	9	Crohn's anal fistula
Meinero and Mori [108]	2011	VAAFT	136	87.1%	0	-	-	12	complex anal fistula

ing process (GMP), grade-derived stem cells, biomaterials, mass manufacturing, and surgical issues are addressed carefully. This approach can prepare conditions for bottom-up tissue regeneration inside the fistula.

#### Declaration of Competing Interest

None.

#### CRediT authorship contribution statement

**Hojjatollah Nazari:** Visualization, Data curation, Formal analysis, Writing – original draft, Investigation. **Zahra Ebrahim Soltani:** Visualization, Data curation, Formal analysis, Writing – original draft, Investigation. **Reza Akbari Asbagh:** Visualization, Data curation, Writing – original draft, Investigation. **Amirsina Sharifi:** Data curation, Investigation. **Abolfazl Badripour:** Data curation, Writing – original draft, Investigation. **Asieh Heirani Tabasi:** Data curation, Investigation. **Majid Ebrahimi Warkiani:** Data curation, Investigation. **Mohammad Reza Keramati:** Data curation, Formal analysis, Writing – original draft, Investigation. **Behnam Behboodi:** Data curation, Formal analysis, Investigation. **Mohammad Sadegh Fazeli:** Data curation, Formal analysis, Investigation. **Amir Keshvari:** Data curation, Formal analysis, Investigation. **Mojgan Rahimi:** Data curation, Investigation. **Seyed Mohsen Ahmadi Tafti:** Visualization, Data curation, Formal analysis, Writing – original draft, Investigation.

#### Acknowledgment

There is no conflict of interest between authors.

#### Supplementary materials

Supplementary material associated with this article can be found, in the online version, at doi:10.1016/j.hsr.2022.100026.

#### References

- [1] M. Abdelhameed, I. Elghazawy, E. Elsayed, Study the role of loose versus cutting of seton in treatment of high perianal fistula in a district hospital of health insurance, *QJM Int. J. Med.* 113 (Supplement\_1) (2020) 24 hcaa050.
- [2] M.A.K. Motamedi, S. Serahati, L. Rajendran, C.J. Brown, M.J. Raval, A. Karimuddin, et al., Long-term outcomes after seton placement for perianal fistulae with and without Crohn's disease, *Colorectal Dis.* 23 (2022) 2407–2415.
- [3] A. Gklavas, I. Sotirova, M. Karageorgou, T. Kozonis, A. Poulaki, I. Papaconstantinou, Is the quality of life of patients with fistulizing perianal Crohn's disease impaired by the presence of chronic loose, non-cutting seton? *J. Gastrointest. Surg.* 25 (2021) 1–4.
- [4] H. Nazari, V.Y. Naei, A.H. Tabasi, A. Badripour, R. Akbari Asbagh, M.R. Keramati, et al., Advanced regenerative medicine strategies for treatment of perianal fistula in Crohn's disease, *Inflamm. Bowel Dis.* 28 (2021) 133–142.
- [5] G. Bisceglia, M. Santodirocco, A. Faienza, N. Mastrodonato, F. Urbano, A. Totaro, et al., First endocavitary treatment with cord blood platelet gel for perianal fistula, *Regen. Med.* 15 (1) (2020) 1171–1176.
- [6] G.W. Dryden, E. Boland, V. Yajnik, S. Williams, Comparison of stromal vascular fraction with or without a novel bioscaffold to fibrin glue in a porcine model of mechanically induced anorectal fistula, *Inflamm. Bowel Dis.* 23 (11) (2017) 1962–1971.
- [7] Y. Zhang, M. Ni, C. Zhou, Y. Wang, Y. Wang, Y. Shi, et al., Autologous adipose-derived stem cells for the treatment of complex cryptoglandular perianal fistula: a prospective case-control study, *Stem Cell Res. Ther.* 11 (1) (2020) 1–10.
- [8] D.L. Franco, S.D. Holubar, A.L. Lightner, B.A. Lashner, B. Shen, Local Stem Cell Therapy for Crohn's Perianal Fistulae, Oxford University Press US, 2019.
- [9] S.R. Vavricka, G. Rogler, Fistula treatment: the unresolved challenge, *Dig. Dis.* 28 (3) (2010) 556–564.
- [10] S.M. Raslan, M. Aladwani, N. Alsanee, Evaluation of the cutting seton as a method of treatment for perianal fistula, *Ann. Saudi Med.* 36 (3) (2016) 210–215.
- [11] P. Tozer, P. Lung, A. Lobo, S. Sebastian, S. Brown, A. Hart, et al., Pathogenesis of Crohn's perianal fistula—understanding factors impacting on success and failure of treatment strategies, *Aliment. Pharmacol. Ther.* 48 (3) (2018) 260–269.
- [12] S.H. Feroz, A. Ahmed, A. Muralidharan, P. Thirunavukarasu, Comparison of the efficacy of the various treatment modalities in the management of perianal Crohn's fistula: a review, *Cureus* 12 (12) (2020) 1–19.
- [13] M. Kelly, H. Heneghan, F. McDermott, G. Nason, C. Freeman, S. Martin, et al., The role of loose seton in the management of anal fistula: a multicenter study of 200 patients, *Tech. Coloproctol.* 18 (10) (2014) 915–919.
- [14] J.G. Williams, C.A. MacLeod, D.A. Rothenberger, S.M. Goldberg, Seton treatment of high anal fistulae, *Br. J. Surg.* 78 (10) (2005) 1159–1161.
- [15] M. Mehanna, A.M. Ahmed, Comparison between rubber band and Ethelon suture as a cutting seton in perianal fistula, *Egypt. J. Hosp. Med.* 71 (4) (2018) 3032–3038.
- [16] M.E. Stellingwerf, M.T.J. Bak, E.J. de Groof, C.J. Buskens, C.B.H. Molenaar, K.B. Gecke, et al., Knotless seton for perianal fistulas: feasibility and effect on perianal disease activity, *Sci. Rep.* 10 (1) (2020) 16693.
- [17] M. Akici, O. Ersen, The effect of suture selection in complex anal fistulas on the success of cutting seton placement and patient comfort, *Pak. J. Med. Sci.* 36 (4) (2020) 816.
- [18] G. Buchanan, H. Owen, J. Torkington, P. Lunniss, R. Nicholls, C. Cohen, Long-term outcome following loose-seton technique for external sphincter preservation in complex anal fistula, *Br. J. Surg.* 91 (4) (2004) 476–480.
- [19] D. Garcia-Olmo, D. Herreros, I. Pascual, J.A. Pascual, E. Del-Valle, J. Zorrilla, et al., Expanded adipose-derived stem cells for the treatment of complex perianal fistula: a phase II clinical trial, *Dis. Colon Rectum* 52 (1) (2009) 79–86.
- [20] M.S. El Mohamady, Cutting seton in management of complex perianal fistula—is it a safe procedure? *Menoufia Med. J.* 31 (3) (2018) 867.
- [21] B. André, A. Bär, A. Haverich, A. Hilfiker, Small intestinal submucosa segments as matrix for tissue engineering, *Tissue Eng. B Rev.* 19 (4) (2013) 279–291.
- [22] Y.Y. Chan, M.I. Bury, E.M. Yura, M.D. Hofer, E.Y. Cheng, A.K. Sharma, The current state of tissue engineering in the management of hypospadias, *Nat. Rev. Urol.* 17 (3) (2020) 162–175.
- [23] Q. Denost, J.P. Adam, A. Pontallier, A. Montebault, R. Bareille, R. Siadous, et al., Colorectal tissue engineering: a comparative study between porcine small intestinal submucosa (SIS) and chitosan hydrogel patches, *Surgery* 158 (6) (2015) 1714–1723.
- [24] E.L. McConnell, S. Murdan, A.W. Basit, An investigation into the digestion of chitosan (noncrosslinked and crosslinked) by human colonic bacteria, *J. Pharm. Sci.* 97 (9) (2008) 3820–3829.
- [25] M. Herreros, D. Garcia-Olmo, H. Guadalajara, T. Georgiev-Hristov, L. Brandariz, M. Garcia-Arnan, Stem cell therapy: a compassionate use program in perianal fistula, *Stem Cells Int.* 2019 (2019) 1–6.
- [26] X. Xia, K.F. Chan, G.T.Y. Wong, P. Wang, L. Liu, B.P.M. Yeung, et al., Mesenchymal stem cells promote healing of nonsteroidal anti-inflammatory drug-related peptic ulcer through paracrine actions in pigs, *Sci. Transl. Med.* 11 (516) (2019).
- [27] G.E. Theodoropoulos, E. Mihailidou, G.N. Kolovos, The role of stem cells in the treatment of anal fistulas, in: *Digestive System Diseases*, Springer, 2019, pp. 113–135.
- [28] Malasevskiaia I., Al-Awadhi A.A., Raza FA. Adipose-derived stem cells—a promising method of therapy for perianal fistula: a traditional review, *J. Middle East North Afr. sci* 7 (5) (2022) 8 - 17.
- [29] L. Ghasemi-Mobarakeh, M.P. Prabhakaran, L. Tian, E. Shamirzaei-Jeshvaghani, L. Dehghani, S. Ramakrishna, Structural properties of scaffolds: crucial parameters towards stem cells differentiation, *World J. Stem Cells* 7 (4) (2015) 728.
- [30] M.U. Aslam Khan, S.I. Abd Razak, W.S. Al Arjan, S. Nazir, T.J. Sahaya Anand, H. Mehboob, et al., Recent advances in biopolymeric composite materials for tissue engineering and regenerative medicines: a review, *Molecules* 26 (3) (2021) 619.
- [31] K. Ashtari, H. Nazari, H. Ko, P. Tebon, M. Akhshik, M. Akbari, et al., Electrically conductive nanomaterials for cardiac tissue engineering, *Adv. Drug. Deliv. Rev.* 144 (2019) 162–179.
- [32] N. Poomathi, S. Singh, C. Prakash, A. Subramanian, R. Sahay, A. Cinappan, et al., 3D printing in tissue engineering: a state of the art review of technologies and biomaterials, *Rapid Prototyp. J.* 26 (7) (2020) 1313–1334.
- [33] S.R. Shin, C. Zihlmann, M. Akbari, P. Assawes, L. Cheung, K. Zhang, et al., Reduced graphene oxide-gelMA hybrid hydrogels as scaffolds for cardiac tissue engineering, *Small* 12 (27) (2016) 3677–3689.
- [34] H. Karagoz, F. Zor, E. Goktas, V.S. Gorantla, Adipogenesis for soft tissue reconstruction, *Curr. Opin. Organ Transp.* 24 (5) (2019) 598–603.
- [35] P. Abdollahiyan, F. Oroojalian, A. Mokhtarzadeh, The triad of nanotechnology, cell signalling, and scaffold implantation for the successful repair of damaged organs: an overview on soft-tissue engineering, *J. Control. Release* 332 (2021) 460–492.
- [36] E. Mostafavi, P. Soltantabar, T.J. Webster, Nanotechnology and picotechnology: a new arena for translational medicine, in: *Biomaterials in Translational Medicine*, Elsevier, 2019, pp. 191–212.
- [37] A. Ashraf, F. Aman, S. Movassaghi, A. Zafar, M. Kubanik, W.A. Siddiqui, et al., Structural modifications of the anti-inflammatory oxamic scaffold and preparation of anticancer organometallic compounds, *Organometallics* 38 (2) (2019) 361–374.
- [38] Z. Wei, L. Wang, S. Zhang, T. Chen, J. Yang, S. Long, et al., Electrospun antibacterial nanofibers for wound dressings and tissue medicinal fields: a review, *J. Innov. Opt. Health Sci.* 13 (5) (2020) 2030012.
- [39] I.R. Calori, G. Braga, BiH de Jesus PdCC, A.C. Tedesco, Polymer scaffolds as drug delivery systems, *Eur. Polym. J.* 129 (2020) 109621.
- [40] J.M. Unagolla, A.C. Jayasuriya, Hydrogel-based 3D bioprinting: A comprehensive review on cell-laden hydrogels, bioink formulations, and future perspectives, *Applied materials today* 18 (2020) 100479.
- [41] A.K. Badekila, S. Kini, A.K. Jaiswal, Fabrication techniques of biomimetic scaffolds in three-dimensional cell culture: a review, *J. Cell. Physiol.* 236 (2) (2021) 741–762.
- [42] S. Joshi, K. Rawat, C. Karunakaran, V. Rajamohan, A.T. Mathew, K. Koziol, et al., 4D printing of materials for the future: opportunities and challenges, *Appl. Mater. Today* 18 (2020) 100490.
- [43] M. Champeau, D.A. Heinze, T.N. Viana, E.R. de Souza, A.C. Chinellato, S. Titotto, 4D printing of hydrogels: a review, *Adv. Funct. Mater.* 30 (31) (2020) 1910606.
- [44] E.B. Snider, J.A. Maykel, Anal abscess and fistula, *Gastroenterol. Clin. N. Am.* 42 (4) (2013) 773–784.

- [45] M.E. Stellingwerf, E.M. Van Praag, P.J. Tozer, W.A. Bemelman, C.J. Buskens, Systematic review and meta-analysis of endorectal advancement flap and ligation of the intersphincteric fistula tract for cryptoglandular and Crohn's high perianal fistulas, *BJS Open* 3 (3) (2019) 231–241.
- [46] X.C. Cheung, T. Fahey, A.C. Rogers, J.H. Pemberton, D.O. Kavanagh, Surgical management of idiopathic perianal fistulas: a systematic review and meta-analysis, *Dig. Surg.* 38 (2021) 1–16.
- [47] M.E. Kelly, H.M. Heneghan, F.D. McDermott, G.J. Nason, C. Freeman, S.T. Martin, et al., The role of loose seton in the management of anal fistula: a multicenter study of 200 patients, *Tech. Coloproctol.* 18 (10) (2014) 915–919.
- [48] J.D. Vogel, E.K. Johnson, A.M. Morris, I.M. Paquette, T.J. Saclarides, D.L. Feingold, et al., Clinical practice guideline for the management of anorectal abscess, fistula-in-ano, and rectovaginal fistula, *Dis. Colon Rectum* 59 (12) (2016) 1117–1133.
- [49] A.G. Parks, P.H. Gordon, J.D. Hardcastle, A classification of fistula-in-ano, *J. Br. Surg.* 63 (1) (1976) 1–12.
- [50] D. Held, I. Khubchandani, J. Sheets, J. Stasik, L. Rosen, R. Riether, Management of anorectal horseshoe abscess and fistula, *Dis. Colon Rectum* 29 (12) (1986) 793.
- [51] F. Litta, A. Parello, L. Ferri, N.O. Torrecilla, A.A. Marra, R. Orefice, et al., Simple fistula-in-ano: is it all simple? A systematic review, *Tech. Coloproctol.* 25 (4) (2021) 385–399.
- [52] C.B. Geltzeiler, N. Wiegand, V.L. Tsikitis, Recent developments in the surgical management of perianal fistula for Crohn's disease, *Ann. Gastroenterol. Q. Publ. Hellenic Soc. Gastroenterol.* 27 (4) (2014) 320.
- [53] A. Rojanasakul, J. Pattanaarun, C. Sahakitrungruang, K. Tantiphlachiva, Total anal sphincter saving technique for fistula-in-ano; the ligation of intersphincteric fistula tract, *J. Med. Assoc. Thai.* 90 (3) (2007) 581–586.
- [54] C. Mushaya, L. Bartlett, B. Schulze, Y.H. Ho, Ligation of intersphincteric fistula tract compared with advancement flap for complex anorectal fistulas requiring initial seton drainage, *Am. J. Surg.* 204 (3) (2012) 283–289.
- [55] O.I. Al Sebai, M.S. Ammar, S.H. Mohamed, M.A. El Balsby, Comparative study between intersphincteric ligation of perianal fistula versus conventional fistulotomy with or without seton in the treatment of perianal fistula: a prospective randomized controlled trial, *Ann. Med. Surg.* 61 (2021) 180–184 2012.
- [56] J.S. Tsang, T.Y. Chan, H.H. Cheung, R. Wei, C.C. Foo, OSH. Lo, Porcine dermal collagen mesh (Permacol™) as a bioprosthesis in the ligation of intersphincteric tract (BioLIFT) procedure, *Tech. Coloproctol.* 24 (12) (2020) 1277–1283.
- [57] K. Wen, Y.F. Gu, X.L. Sun, X.P. Wang, S. Yan, Z.Q. He, et al., Long-term outcomes of ligation of intersphincteric fistula tract for complex fistula-in-ano: modified operative procedure experience, *Arq. Bras. Cir. Dig. ABCD Braz. Arch. Dig. Surg.* 31 (4) (2018) e1404.
- [58] W.H. Kang, H.K. Yang, H.J. Chang, Y.T. Ko, B.E. Yoo, C.H. Lim, et al., High ligation of the anal fistula tract by lateral approach: a prospective cohort study on a modification of the ligation of the intersphincteric fistula tract (LIFT) technique, *Int. J. Surg.* 60 (2018) 9–14 London, England.
- [59] Y.C. Lau, K.G.M. Brown, J. Cheong, C. Byrne, P.J. Lee, LIFT and BioLIFT: a 10-year single-centre experience of treating complex fistula-in-ano with ligation of intersphincteric fistula tract procedure with or without bio-prosthetic reinforcement (BioLIFT), *J. Gastrointest. Surg. Off. J. Soc. Surg. Alim. Tract.* 24 (3) (2020) 671–676.
- [60] J. Osterkamp, P. Gocht-Jensen, K. Hougaard, T. Nordentoft, Long-term outcomes in patients after ligation of the intersphincteric fistula tract, *Dan. Med. J.* 66 (4) (2019) 1–6.
- [61] J.P. Kamiński, K. Zaghiyan, P. Fleshner, Increasing experience of ligation of the intersphincteric fistula tract for patients with Crohn's disease: what have we learned? *Colorectal Dis.* 19 (8) (2017) 750–755.
- [62] E.M. van Praag, M.E. Stellingwerf, J.D.W. van der Bilt, W.A. Bemelman, K.B. Gecke, C.J. Buskens, Ligation of the intersphincteric fistula tract and endorectal advancement flap for high perianal fistulas in Crohn's disease: a retrospective cohort study, *J. Crohn Colitis* 14 (6) (2020) 757–763.
- [63] A. Mujukian, A. Truong, P. Fleshner, K. Zaghiyan, Long-term healing after complex anal fistula repair in patients with Crohn's disease, *Tech. Coloproctol.* 24 (8) (2020) 833–841.
- [64] K.M. Madbouly, S.H. Emile, Y.A. Issa, W. Omar, Ligation of intersphincteric fistula tract (LIFT) with or without injection of platelet-rich plasma (PRP) in management of high trans-sphincteric fistula-in-ano: short-term outcomes of a prospective, randomized trial, *Surgery* 170 (2021) 61–66.
- [65] E.M. Meima-van Praag, K.L. van Rijn, M.A. Monraats, C.J. Buskens, J. Stoker, Magnetic resonance imaging after ligation of the intersphincteric fistula tract for high perianal fistulas in Crohn's disease: a retrospective cohort study, *Colorectal Dis.* 23 (1) (2021) 169–177.
- [66] M.F. Celayir, E. Bozkurt, N. Aygun, M. Mihmanli, Complex anal fistula: long-term results of modified ligation of intersphincteric fistula tract=LIFT, *Sisli Etfal Hastan. Bul.* 54 (3) (2020) 297–301.
- [67] I.C. Eray, A. Rencuzogullari, Endosonography-confirmed long-term outcomes of ligation of the intersphincteric fistula tract procedure for complex perianal fistulas, *Ann. Ital. Chir.* 91 (2020) 512–519.
- [68] Y.F. Wu, B.C. Zheng, Q. Chen, X.D. Chen, S.S. Ye, Q.Y. Lin, et al., Video-assisted modified ligation of the intersphincteric fistula tract, an integration of 2 minimally invasive techniques for the treatment of parks type II anal fistulas, *Surg. Innov.* 28 (2020) 419–426 1553350620978026.
- [69] M. Sarmiento-Cobos, L. Rosen, E. Wasser, F. Yang, S.D. Wexner, High failure rates following ligation of the intersphincteric fistula tract for transsphincteric anal fistulas: are preoperative MRI measurements of the fistula tract predictive of outcome? *Colorectal Dis.* 23 (2020) 932–936.
- [70] S. Van Hoof, E. Van Dessel, P. Cools, LIFT: a feasible option for primary and recurrent fistulas, *Acta Chir. Belg.* 121 (2020) 1–7.
- [71] W. Wanitsuwan, K. Junmitsakul, S. Jearanai, V. Lohsiriwat, Video-assisted ligation of intersphincteric fistula tract for complex anal fistula: technique and preliminary outcomes, *Dis. Colon Rectum* 63 (11) (2020) 1534–1540.
- [72] X. Dong, Z. Jia, B. Yu, X. Zhang, F. Xu, L. Tan, Effect of intersphincteric fistula tract ligation versus anal fistulectomy on pain scores and serum levels of vascular endothelial growth factor and interleukin-2 in patients with simple anal fistulas, *J. Int. Med. Res.* 48 (9) (2020) 300060520949072.
- [73] N.K. Raja Ram, K.K. Chan, S.F. Md Nor, I. Sagap, A prospective evaluation of the outcome of submucosal ligation of fistula tract, *Colorectal Dis.* 22 (12) (2020) 2199–2203.
- [74] T.M. Zwiap, R. Gilbert, R.P. Boushey, S. Schmid, H. Moloo, I. Raiche, et al., Comparison of ligation of the intersphincteric fistula tract and BioLIFT for the treatment of transsphincteric anal fistula: a retrospective analysis, *Dis. Colon Rectum* 63 (3) (2020) 365–370.
- [75] P. Cianci, N. Tartaglia, A. Fersini, L.L. Giambavichio, V. Neri, A. Ambrosi, The ligation of intersphincteric fistula tract technique: a preliminary experience, *Ann. Coloproctol.* 35 (5) (2019) 238–241.
- [76] K.W.A. Göttgens, D.K. Wasowicz, J. Stijns, D. Zimmerman, Ligation of the intersphincteric fistula tract for high transsphincteric fistula yields moderate results at best: is the tide turning? *Dis. Colon Rectum* 62 (10) (2019) 1231–1237.
- [77] G.J.H. Vander Mijnsbrugge, R.J.F. Felt-Bersma, D.K.F. Ho, C.B.H. Molenaar, Perianal fistulas and the lift procedure: results, predictive factors for success, and long-term results with subsequent treatment, *Tech. Coloproctol.* 23 (7) (2019) 639–647.
- [78] B. Zhao, Z. Wang, J. Han, Y. Zheng, J. Cui, S. Yu, Long-term outcomes of ligation of the inter-sphincteric fistula tract plus bioprosthesis anal fistula plug (LIFT-Plug) in the treatment of trans-sphincteric perianal fistula, *Med. Sci. Monit.* 25 (2019) 1350–1354.
- [79] X.L. Sun, K. Wen, Y.H. Chen, Z.Z. Xu, X.P. Wang, Long-term outcomes and quality of life following ligation of the intersphincteric fistula tract for high transsphincteric fistulas, *Colorectal Dis.* 21 (1) (2019) 30–37.
- [80] S.E.A. Araújo, M.T. Marcante, C.R.S. Mendes, A.B. Bertoncini, V.E. Seid, L.A. Horcel, et al., Interesfincterial ligation of fistula tract (lift) for patients with anal fistulas: a Brazilian bi-institutional experience, *Arq. Bras. Cir. Dig. ABCD Braz. Arch. Dig. Surg.* 30 (4) (2017) 235–238.
- [81] S. Malakorn, T. Samsour, S. Khomvilai, I. Chowchankit, S. Gunaras, P. Kanjanasilp, et al., Ligation of intersphincteric fistula tract for fistula in ano: lessons learned from a decade of experience, *Dis. Colon Rectum* 60 (10) (2017) 1065–1070.
- [82] C. Placer Galán, C. Lopes, J.A. Múgica, Y. Saralegui, N. Borda, J.M. Enriquez Navascues, Patterns of recurrence/persistence of cryptoglandular anal fistula after the LIFT procedure. Long-term observational study, *Cir. Esp.* 95 (7) (2017) 385–390.
- [83] Y. Xu, W. Tang, Ligation of intersphincteric fistula tract is suitable for recurrent anal fistulas from follow-up of 16 months, *Biomed. Res. Int.* 2017 (2017) 3152424.
- [84] H.J. Chen, G.D. Sun, P. Zhu, Z.L. Zhou, Y.G. Chen, B.L. Yang, Effective and long-term outcome following ligation of the intersphincteric fistula tract (LIFT) for transsphincteric fistula, *Int. J. Colorectal Dis.* 32 (4) (2017) 583–585.
- [85] A. Wilhelm, A. Fiebig, M. Krawczak, Five years of experience with the FiLaC™ laser for fistula-in-ano management: long-term follow-up from a single institution, *Tech. Coloproctol.* 21 (4) (2017) 269–276.
- [86] P. Giamundo, L. Esercizio, M. Geraci, L. Tibaldi, M. Valente, Fistula-tract laser closure (FiLaC™): long-term results and new operative strategies, *Tech. Coloproctol.* 19 (8) (2015) 449–453.
- [87] A. Wilhelm, A new technique for sphincter-preserving anal fistula repair using a novel radial emitting laser probe, *Tech. Coloproctol.* 15 (4) (2011) 445–449.
- [88] P. Giamundo, M. Geraci, L. Tibaldi, M. Valente, Closure of fistula-in-ano with laser-FiLaC™: an effective novel sphincter-saving procedure for complex disease, *Colorectal Dis.* 16 (2) (2014) 110–115.
- [89] A. Wolicki, P. Jäger, T. Deska, M. Senkal, Sphincter-saving therapy for fistula-in-ano: long-term follow-up after FiLaC(®), *Tech. Coloproctol.* 25 (2) (2021) 177–184.
- [90] M. Frountzas, K. Stergios, C. Nikolaou, I. Bellos, D. Schizas, D. Linardoutsos, et al., Could FiLaCTM be effective in the treatment of anal fistulas? A systematic review of observational studies and proportional meta-analysis, *Colorectal Dis.* 22 (2020) 1874–1884.
- [91] I. Marref, L. Spindler, M. Aubert, N. Lemarchand, N. Fathallah, E. Pommaret, et al., The optimal indication for FiLaC(®) is high trans-sphincteric fistula-in-ano: a prospective cohort of 69 consecutive patients, *Tech. Coloproctol.* 23 (9) (2019) 893–897.
- [92] D.E. Brabender, K.L. Moran, M. Brady, J.C. Carmichael, S. Mills, A. Pigazzi, et al., Assessing the effectiveness of laser fistulotomy for anal fistula: a retrospective cohort study, *Tech. Coloproctol.* 24 (10) (2020) 1071–1075.
- [93] K.R. Serin, N.A. Hacim, O. Karabay, M.C. Terzi, Retrospective analysis of primary suturing of the internal orifice of perianal fistula during FiLaC procedure, *Surg. Laparosc. Endosc. Percutan. Tech.* 30 (3) (2020) 266–269.
- [94] A. Alam, F. Lin, N. Fathallah, E. Pommaret, M. Aubert, N. Lemarchand, et al., FiLaC(®) and Crohn's disease perianal fistulas: a pilot study of 20 consecutive patients, *Tech. Coloproctol.* 24 (1) (2020) 75–78.
- [95] A. Kirschniak, T. Kratt, D. Stüker, A. Braun, M.O. Schurr, A. Königsrainer, A new endoscopic Over-The-Scope Clip System for treatment of lesions and bleeding in the GI tract: first clinical experiences, *Gastrointest. Endosc.* 66 (1) (2007) 162–167.
- [96] R.L. Probst, A. Herold, A.K. Joos, D. Bussen, M. Wehrmann, T. Gottwald, et al., The anal fistula claw: the OTSC clip for anal fistula closure, *Colorectal Dis.* 14 (9) (2012) 1112–1117.

- [97] D. Mascagni, D. Pironi, G. Grimaldi, A.M. Romani, G. La Torre, C. Eberspacher, et al., OTSC® proctology vs. fistulectomy and primary sphincter reconstruction as a treatment for low trans-sphincteric anal fistula in a randomized controlled pilot trial, *Minerva Chir.* 74 (1) (2019) 1–6.
- [98] R. Mennigen, M. Laukötter, N. Senninger, E. Rijcken, The OTSC® proctology clip system for the closure of refractory anal fistulas, *Tech. Coloproctol.* 19 (4) (2015) 241–246.
- [99] R.L. Prosst, A.K. Joos, Short-term outcomes of a novel endoscopic clipping device for closure of the internal opening in 100 anorectal fistulas, *Tech. Coloproctol.* 20 (11) (2016) 753–758.
- [100] R.L. Prosst, A.K. Joos, W. Ehni, D. Bussen, A. Herold, Prospective pilot study of anorectal fistula closure with the OTSC Proctology, *Colorectal Dis.* 17 (1) (2015) 81–86.
- [101] R.L. Prosst, W. Ehni, A.K. Joos, The OTSC® Proctology clip system for anal fistula closure: first prospective clinical data, *Minim. Invasive Ther. Allied Technol. MITAT Off. J. Soc. Minim. Invasive Ther.* 22 (5) (2013) 255–259.
- [102] F. Marinello, M. Kraft, N. Ridaura, F. Vallribera, E. Espin, Treatment of fistula-in-ano With OTSC® proctology clip device: short-term results, *Cir. Esp.* 96 (6) (2018) 369–374.
- [103] S.J. Grossberg, N. Harran, B. Bebington, D.L. Lutrin, Use of the OVESCO OTSC® proctology clip for closure of fistula-in-ano at wits donald gordon medical centre - a single centre experience, *S. Afr. J. Surg. Suid Afr. Tydskrif Chir.* 58 (2020) 74–77.
- [104] A. Dubois, G. Carrier, B. Pereira, B. Gillet, J.L. Faucheron, D. Pezet, et al., Therapeutic management of complex anal fistulas by installing a nitinol closure clip: study protocol of a multicentric randomised controlled trial—FISCLOSE, *BMJ Open* 5 (12) (2015) e009884.
- [105] P. Meinero, L. Mori, Video-assisted anal fistula treatment (VAAFT): a novel sphincter-saving procedure for treating complex anal fistulas, *Tech. Coloproctol.* 15 (4) (2011) 417–422.
- [106] Y. Zhang, F. Li, T. Zhao, F. Cao, Y. Zheng, A. Li, Treatment of complex anal fistula by video-assisted anal fistula treatment combined with anal fistula plug: a single-center study, *Surg. Innov.* (2021) 1553350621992924.
- [107] Y. Zhang, F. Li, T. Zhao, F. Cao, Y. Zheng, A. Li, Efficacy of video-assisted anal fistula treatment combined with closure of the internal opening using a stapler for parks II anal fistula, *Ann. Transl. Med.* 8 (22) (2020) 1517.
- [108] P. Meinero, L. Mori, Video-assisted anal fistula treatment (VAAFT): a novel sphincter-saving procedure for treating complex anal fistulas, *Tech. Coloproctol.* 15 (4) (2011) 417–422.
- [109] H. Liu, Y. Xiao, Y. Zhang, Z. Pan, J. Peng, W. Tang, et al., [Preliminary efficacy of video-assisted anal fistula treatment for complex anal fistula], *Chin. J. Gastrointest. Surg.* 18 (12) (2015) 1207–1210.
- [110] H.H. Jiang, H.L. Liu, Z. Li, Y.H. Xiao, A.J. Li, Y. Chang, et al., Video-assisted anal fistula treatment (VAAFT) for complex anal fistula: a preliminary evaluation in China, *Med. Sci. Monit.* 23 (2017) 2065–2071.
- [111] A. Stazi, P. Izzo, F. D'Angelo, M. Radicchi, M. Mazzi, F. Tomassini, et al., Video-assisted anal fistula treatment in the management of complex anal fistula: a single-center experience, *Minerva Chir.* 73 (2) (2018) 142–150.
- [112] H. Liu, X. Tang, Y. Chang, A. Li, Z. Li, Y. Xiao, et al., Comparison of surgical outcomes between video-assisted anal fistula treatment and fistulotomy plus seton for complex anal fistula: a propensity score matching analysis - Retrospective cohort study, *Int. J. Surg.* 75 (2020) 99–104 London, England.
- [113] G. Giarratano, M. Shalaby, C. Toscana, P. Sileri, Video-assisted anal fistula treatment for complex anal fistula: a long-term follow-up study, *Colorectal Dis.* 22 (8) (2020) 939–944.
- [114] L. Regusci, F. Fasolini, P. Meinero, G. Caccia, G. Ruggeri, M. Serati, et al., Video-assisted anal fistula treatment (VAAFT) for complex anorectal fistula: efficacy and risk factors for failure at 3-year follow-up, *Tech. Coloproctol.* 24 (7) (2020) 741–746.
- [115] M. Zelić, D. Karlović, D. Kršul, D. Bačić, J. Warusavitarne, Video-assisted anal fistula treatment for treatment of complex cryptoglandular anal fistulas with 2 years follow-up period: our experience, *J. Laparoendosc. Adv. Surg. Tech. A* 30 (12) (2020) 1329–1333.
- [116] O. Schwandner, Video-assisted anal fistula treatment (VAAFT) combined with advancement flap repair in Crohn's disease, *Tech. Coloproctol.* 17 (2) (2013) 221–225.
- [117] S.O. Adegbola, K. Sahnan, P.J. Tozer, R. Strouhal, A.L. Hart, P.F.C. Lung, et al., Symptom amelioration in Crohn's Perianal fistulas using video-assisted anal fistula treatment (VAAFT), *J. Crohn Colitis* 12 (9) (2018) 1067–1072.
- [118] Y.B. Yao, C.F. Xiao, Q.T. Wang, H. Zhou, Q.J. Dong, Y.Q. Cao, et al., VAAFT plus FiLaC™: a combined procedure for complex anal fistula, *Tech. Coloproctol.* (2021).
- [119] Y. Zhang, F. Li, T. Zhao, F. Cao, Y. Zheng, A. Li, Video-assisted anal fistula treatment combined with anal fistula plug for treatment of horseshoe anal fistula, *J. Int. Med. Res.* 49 (1) (2021) 300060520980525.
- [120] M. La Torre, G. Lisi, E. D'Agostino, M. Boccuzzi, M. Campanelli, M. Variiale, et al., Lift and VAAFT for high trans-sphincteric anal fistula: a single center retrospective analysis, *Int. J. Colorectal Dis.* 35 (6) (2020) 1149–1153.
- [121] M.P.J. Lopez, M.A.S. Onglao, H.J. Monroy Iii, Initial experience with video-assisted anal fistula treatment in the Philippines, *Ann. Coloproctol.* 36 (2) (2020) 112–118.
- [122] P. Tozer, K. Sahnan, S. Adegbola, S. Shaikh, P. Lung, Video-assisted anal fistula treatment (VAAFT) assisted seton placement - a video vignette, *Colorectal Dis.* 21 (12) (2019) 1462.
- [123] L. Zheng, J. Lu, Y. Pu, C. Xing, K. Zhao, Comparative study of clinical efficacy between video-assisted anal fistula treatment and traditional fistula resection plus seton in treatment of complex anal fistula, *Chin. J. Gastrointest. Surg.* 21 (7) (2018) 793–797.
- [124] M. Romaniszyn, P. Walega, Video-assisted anal fistula treatment: pros and cons of this minimally invasive method for treatment of perianal fistulas, *Gastroenterol. Res. Pract.* 2017 (2017) 9518310.
- [125] I. Seow-En, F. Seow-Choen, P.K. Koh, An experience with video-assisted anal fistula treatment (VAAFT) with new insights into the treatment of anal fistulae, *Tech. Coloproctol.* 20 (6) (2016) 389–393.
- [126] M. Zarin, M.I. Khan, M. Ahmad, M. Ibrahim, MA. Khan, VAAFT: video assisted anal fistula treatment; bringing revolution in fistula treatment, *Pak. J. Med. Sci.* 31 (5) (2015) 1233–1235.
- [127] G. Kochhar, S. Saha, M. Andley, A. Kumar, G. Saurabh, R. Pusuluri, et al., Video-assisted anal fistula treatment, *JSLs J. Soc. Laparoendosc. Surg.* 18 (3) (2014).
- [128] P. Walega, M. Romaniszyn, W. Nowak, VAAFT: a new minimally invasive method in the diagnostics and treatment of anal fistulas—initial results, *Pol. Przegl. Chir.* 86 (1) (2014) 7–10.
- [129] L. O'Connor, B.J. Champagne, M.A. Ferguson, G.R. Orangio, M.E. Schertzer, D.N. Armstrong, Efficacy of anal fistula plug in closure of Crohn's anorectal fistulas, *Dis. Colon Rectum* 49 (10) (2006) 1569–1573.
- [130] O. Schwandner, F. Stadler, O. Dietl, R. Wirsching, A. Fuerst, Initial experience on efficacy in closure of cryptoglandular and Crohn's transsphincteric fistulas by the use of the anal fistula plug, *Int. J. Colorectal Dis.* 23 (3) (2008) 319–324.
- [131] P.J. van Koperen, A. D'Hoore, A.M. Wolthuis, W.A. Bemelman, J.F.M. Slors, Anal fistula plug for closure of difficult anorectal fistula: a prospective study, *Dis. Colon Rectum* 50 (12) (2007) 2168–2172.
- [132] B.J. Champagne, L.M. O'Connor, M. Ferguson, G.R. Orangio, M.E. Schertzer, D.N. Armstrong, Efficacy of anal fistula plug in closure of cryptoglandular fistulas: long-term follow-up 49 (12) (2006) 1817–1821.
- [133] D. Christoforidis, M.C. Pieh, R.D. Madoff, AF. Mellgren, Treatment of transsphincteric anal fistulas by endorectal advancement flap or collagen fistula plug: a comparative study, *Dis. Colon Rectum* 52 (1) (2009) 18–22.
- [134] A.J. Ky, P. Sylla, R. Steinhagen, E. Steinhagen, S. Khaitov, E.K. Ly, Collagen fistula plug for the treatment of anal fistulas, *Dis. Colon Rectum* 51 (6) (2008) 838–843.
- [135] Y. Nasserli, L. Cassella, M. Berns, K. Zaghiyan, J. Cohen, The anal fistula plug in Crohn's disease patients with fistula-in-ano: a systematic review, *Colorectal Dis.* 18 (4) (2016) 351–356.
- [136] S.K. Narang, C. Jones, N.N. Alam, I.R. Daniels, N.J. Smart, Delayed absorbable synthetic plug (GORE® BIO-A®) for the treatment of fistula-in-ano: a systematic review, *Colorectal Dis.* 18 (1) (2016) 37–44.
- [137] J.D. Vogel, E.K. Johnson, A.M. Morris, I.M. Paquette, T.J. Saclarides, D.L. Feingold, et al., Clinical practice guideline for the management of anorectal abscess, fistula-in-ano, and rectovaginal fistula, *Dis. Colon Rectum* 59 (12) (2016) 1117–1133.
- [138] I.T. Jones, V.W. Fazio, D.G. Jagelman, The use of transanal rectal advancement flaps in the management of fistulas involving the anorectum, *Dis. Colon Rectum* 30 (12) (1987) 919–923.
- [139] A. Soltani, AM. Kaiser, Endorectal advancement flap for cryptoglandular or Crohn's fistula-in-ano, *Dis. Colon Rectum* 53 (4) (2010) 486–495.
- [140] V. Rozalén, D. Parés, E. Sanchez, J. Troya, S. Vela, M. Pacha, et al., Advancement flap technique for anal fistula in patients with crohn's disease: a systematic review of the literature, *Cir. Esp.* 95 (10) (2017) 558–565.
- [141] M. Schiano di Visconte, G. Bellio, Comparison of porcine collagen paste injection and rectal advancement flap for the treatment of complex cryptoglandular anal fistulas: a 2-year follow-up study, *Int. J. Colorectal Dis.* 33 (12) (2018) 1723–1731.
- [142] P. Garg, PERFACT procedure to treat supraleural fistula-in-ano: A novel single stage sphincter sparing procedure, *World J. Gastrointest. Surg.* 8 (4) (2016) 326–334.
- [143] P. Garg, M. Garg, PERFACT procedure: a new concept to treat highly complex anal fistula, *World J. Gastroenterol.* 21 (13) (2015) 4020–4029.
- [144] H. Lin, Z. Jin, Y. Zhu, M. Diao, W. Hu, Anal fistula plug vs rectal advancement flap for the treatment of complex cryptoglandular anal fistulas: a systematic review and meta-analysis of studies with long-term follow-up, *Colorectal Dis.* 21 (5) (2019) 502–515.
- [145] J. Jafarzadeh, N. Najibpoor, A. Salmasi, A comparative study on the effectiveness of rectal advancement flap and seton placement surgeries in patients with anal fistula on the rate of recurrence, incontinence and infection, *J. Fam. Med. Prim. Care* 8 (11) (2019) 3591–3594.
- [146] M.E. Stellingwerf, M.T.J. Bak, E.J. de Groof, C.J. Buskens, C.B.H. Molenaar, K.B. Geese, et al., Knotless seton for perianal fistulas: feasibility and effect on perianal disease activity, *Sci. Rep.* 10 (1) (2020) 1–8.
- [147] A.A. Memon, G. Murtaza, R. Azami, H. Zafar, T. Chawla, A.A. Laghari, Treatment of complex fistula in ano with cable-tie seton: a prospective case series, *Int. Sch. Res. Not.* 2011 (2011).
- [148] J. Panés, J. Rimola, Perianal fistulizing Crohn's disease: pathogenesis, diagnosis and therapy, *Nat. Rev. Gastroenterol. Hepatol.* 14 (11) (2017) 652.
- [149] S. Goldberg, A. Shelton, in: *Cutting Seton for Anal Fistulas-High Risk of Minor Control Defects*, WILLIAMS & WILKINS, 1997, pp. 21201–22436. 351 WEST CAMDEN ST, BALTIMORE, MD.
- [150] P.S. Ramanujam, M.L. Prasad, H. Abcarian, A.B. Tan, Perianal abscesses and fistulas, *Dis. Colon Rectum* 27 (9) (1984) 593–597.
- [151] J. Garcia-Aguilar, C. Belmonte, D.W. Wong, S.M. Goldberg, R.D. Madoff, Cutting seton versus two-stage seton fistulotomy in the surgical management of high anal fistula, *Br. J. Surg.* 85 (2) (1998) 243–245.
- [152] J. Panés, J. Rimola, Perianal fistulizing Crohn's disease: pathogenesis, diagnosis and therapy, *Nat. Rev. Gastroenterol. Hepatol.* 14 (11) (2017) 652–664.
- [153] J.S. McCourtney, I.G. Finlay, Cutting seton without preliminary internal sphincterotomy in management of complex high fistula-in-ano, *Dis. Colon Rectum* 39 (1) (1996) 55–58.

- [154] A. Theerapol, B. So, S. Ngoi, Routine use of setons for the treatment of anal fistulae, *Singap. Med. J.* 43 (6) (2002) 305–307.
- [155] W.H. Isbister, N. Al Sanea, The cutting seton: an experience at king faisal specialist hospital, *Dis. Colon Rectum* 44 (5) (2001) 722–727.
- [156] D.R. Rosen, A.M. Kaiser, Definitive seton management for transsphincteric fistula-in-ano: harm or charm? *Colorectal Dis.* 18 (5) (2016) 488–495.
- [157] J.S. McCourtney, I.G. Finlay, Cutting seton without preliminary internal sphincterotomy in management of complex high fistula-in-ano, *Dis. Colon Rectum* 39 (1) (1996) 55–58.
- [158] P.J. van Koperen, W.A. Bemelman, M.F. Gerhards, L.W.M. Janssen, W.F. van Tets, A.D. van Dalsen, et al., The anal fistula plug treatment compared with the mucosal advancement flap for cryptoglandular high transsphincteric perianal fistula: a double-blinded multicenter randomized trial, *Dis. Colon Rectum* 54 (4) (2011) 387–393.
- [159] S.J. van der Hagen, C.G. Baeten, P.B. Soeters, W.G. van Gemert, Long-term outcome following mucosal advancement flap for high perianal fistulas and fistulotomy for low perianal fistulas, *Int. J. Colorectal Dis.* 21 (8) (2006) 784–790.
- [160] W.R. Schouten, D.D. Zimmerman, J.W. Briel, Transanal advancement flap repair of transsphincteric fistulas, *Dis. Colon Rectum* 42 (11) (1999) 22–23 1419–22; discussion.
- [161] G. Vander Mijnsbrugge, R. Felt-Bersma, D. Ho, C. Molenaar, Perianal fistulas and the lift procedure: results, predictive factors for success, and long-term results with subsequent treatment, *Tech. Coloproctol.* 23 (7) (2019) 639–647.
- [162] A. Cariati, Fistulotomy or seton in anal fistula: a decisional algorithm, *Updates Surg.* 65 (3) (2013) 201–205.
- [163] S.H. Emile, H. Elfeki, W. Thabet, A. Sakr, A. Magdy, T.M. Abd El-Hamed, et al., Predictive factors for recurrence of high transsphincteric anal fistula after placement of seton, *J. Surg. Res.* 213 (2017) 261–268.
- [164] R. Ritchie, J. Sackier, J. Hodde, Incontinence rates after cutting seton treatment for anal fistula, *Colorectal Dis.* 11 (6) (2009) 564–571.
- [165] S. Gülmez, An 8 Years' experience in surgical treatment of anal fistula, *Ann. Med. Res.* 27 (8) (2020) 2031–2035.
- [166] A. Lykke, J. Steendahl, P.A. Wille-Jørgensen, [Treating high anal fistulae with slow cutting seton], *Ugeskr Laeger* 172 (7) (2010) 516–519.
- [167] M. Vial, D. Parés, M. Pera, L. Grande, Faecal incontinence after seton treatment for anal fistulae with and without surgical division of internal anal sphincter: a systematic review, *Colorectal Dis.* 12 (3) (2010) 172–178.
- [168] H. Hasegawa, S. Radley, M.R. Keighley, Long-term results of cutting seton fistulotomy, *Acta Chir. Iugosl.* 47 (4) (2000) 19–21 Suppl 1.
- [169] B.B. Mentés, S. Öktemer, T. Tezcaner, C. Azılı, S. Leventoğlu, M. Oğuz, Elastic one-stage cutting seton for the treatment of high anal fistulas: preliminary results, *Tech. Coloproctol.* 8 (3) (2004) 159–162.
- [170] A. Munir, S.Q. Falah, Management of high fistula in ano with cutting seton, *Gomal J. Med. Sci.* 12 (4) (2014) 210–212.
- [171] J.F. Zhang, Records of bizarre Jurassic brachycerans in the Daohugou biota, China (Diptera, brachycera, archisargidae and rhagionemestriidae), *Palaeontology* 53 (2) (2010) 307–317.
- [172] K.P.J. Hämäläinen, A.P. Sainio, Cutting seton for anal fistulas, *Dis. Colon Rectum* 40 (12) (1997) 1443–1447.
- [173] M.C. Misra, B.M.L. Kapur, A new non-operative approach to fistula in ano, *BJS Br. J. Surg.* 75 (11) (1988) 1093–1094.
- [174] C. Hyman, Use of braided wire seton for two-stage anorectal fistula operation: preliminary report, *AMA Arch. Surg.* 71 (6) (1955) 890–891.
- [175] M.E. Pezim, Successful treatment of horseshoe fistula requires deroofting of deep postanal space, *Am. J. Surg.* 167 (5) (1994) 513–515.
- [176] C.E. Culp, Use of penrose drains to treat certain anal fistulas: a primary operative seton, *Mayo Clin. Proc.* 59 (9) (1984) 613–617.
- [177] S. Leventoğlu, B. Ege, B. Mentés, M. Yürübulut, S. Soydan, B. Aytaç, Treatment for horseshoe fistula with the modified Hanley procedure using a hybrid seton: results of 21 cases, *Tech. Coloproctol.* 17 (4) (2013) 411–417.
- [178] C. Chuang-Wei, W. Chang-Chieh, H. Cheng-Wen, L. Tsai-Yu, F. Chun-Che, J. Shu-Wen, Cutting seton for complex anal fistulas, *Surgeon* 6 (3) (2008) 185–188.
- [179] B. Mentés, S. Öktemer, T. Tezcaner, C. Azılı, S. Leventoğlu, M. Oğuz, Elastic one-stage cutting seton for the treatment of high anal fistulas: preliminary results, *Tech. Coloproctol.* 8 (3) (2004) 159–162.
- [180] P.H. Hanley, Rubber band seton in the management of abscess-anal fistula, *Ann. Surg.* 187 (4) (1978) 435–437.
- [181] O.Y. Karpukhin, K. Sakulin, Use of rubber seton in the treatment of anorectal fistulae, *Kazan Med. J.* 99 (2) (2018) 326–329.
- [182] B.H. Shirah, H.A. Shirah, The impact of the outcome of treating a high anal fistula by using a cutting seton and staged fistulotomy on Saudi Arabian patients, *Ann. Coloproctol.* 34 (5) (2018) 234–240.
- [183] Y. Celik, M.Z. Buldanli, Comparison of loose silk and tightenable polypropylene seton placement in treatment of complex anal fistula, *Age* 42 (12.1) (2021) 43.00.
- [184] O.A.V. Tanus, C. Santos, D.M. Dourado, A.L. Conde, F. Giuncanse, I.F. Souza, et al., Primary sphincteroplasty comparing two different stitches in anal fistula treatment: experimental study in rats, *Arq. Bras. Cir. Dig. ABCD Braz. Arch. Dig. Surg.* 32 (3) (2019) e1459.
- [185] B.H. Shirah, H.A. Shirah, The impact of the outcome of treating a high anal fistula by using a cutting seton and staged fistulotomy on Saudi Arabian patients, *Ann. Coloproctol.* 34 (5) (2018) 234.
- [186] Y. Celik, M.Z. Buldanli, Comparison of loose silk and tightenable polypropylene seton placement in treatment of complex anal fistula, *Age* 42 (12.1) (2022) 43.00.
- [187] A. Al-Wadees, S. Al-Hakkak, M. Akool, Two staged operations using loose thick seton suture in the treatment of high type fistula in ano stimulate rapid healing and lower recurrence rate, *Prensa Med. Argent* 106 (2020) 6.
- [188] J.W. Alexander, J.Z. Kaplan, W.A. Altmeier, Role of suture materials in the development of wound infection, *Ann. Surg.* 165 (2) (1967) 192–199.
- [189] R. Burkhardt, N.P. Lang, Influence of suturing on wound healing, *Periodontol* 68 (1) (2015) 270–281 2000.
- [190] G. Subhas, A. Gupta, S. Balaraman, V.K. Mittal, R. Pearlman, Non-cutting setons for progressive migration of complex fistula tracts: a new spin on an old technique, *Int. J. Colorectal Dis.* 26 (6) (2011) 793–798.
- [191] M. Thornton, M.J. Solomon, Long-term indwelling seton for complex anal fistulas in Crohn's disease, *Dis. Colon Rectum* 48 (3) (2005) 459–463.
- [192] R.A. White, T.E. Eisenstat, R.J. Rubin, E.P. Salvati, Seton management of complex anorectal fistulas in patients with Crohn's disease, *Dis. Colon Rectum* 33 (7) (1990) 587–589.
- [193] C. Verkade, D.D.E. Zimmerman, D.K. Wasowicz, S.W. Polle, H.S. de Vries, Loss of seton in patients with complex anal fistula: a retrospective comparison of conventional knotted loose seton and knot-free seton, *Tech. Coloproctol.* 24 (10) (2020) 1043–1046.
- [194] E. Galis-Rozen, H. Tulchinsky, A. Rosen, S. Eldar, M. Rabau, A. Stepanski, et al., Long-term outcome of loose seton for complex anal fistula: a two-centre study of patients with and without Crohn's disease, *Colorectal Dis.* 12 (4) (2010) 358–362.
- [195] U. Sungurtekin, M. Ozban, H. Erbis, O. Birsen, Loose seton: a misnomer of cutting seton, *Surg. Sci.* 07 (2016) 219–225.
- [196] N. Bakhtawar, M. Usman, Factors increasing the risk of recurrence in fistula-in-ano, *Cureus* 11 (3) (2019) e4200 e.
- [197] G. Atkin, J. Martins, P. Tozer, P. Ranchod, R. Phillips, For many high anal fistulas, lay open is still a good option, *Tech. Coloproctol.* 15 (2) (2011) 143–150.
- [198] I. Papaconstantinou, E. Kontis, V. Koutoulidis, G. Mantzaris, I. Vassiliou, Surgical management of fistula-in-ano among patients with Crohn's disease: analysis of outcomes after fistulotomy or seton placement—single-center experience, *Scand. J. Surg.* 106 (3) (2017) 211–215.
- [199] A. Mujkian, K. Zaghiyan, E. Banayan, P. Fleshner, Outcomes of definitive draining seton placement for complex anal fistula in Crohn's disease, *Am. Surg.* 86 (2020) 0003134820964462.
- [200] I. Kristo, A. Stif, C. Staud, A. Kainz, T. Bachleitner-Hofmann, P. Chitsabesan, et al., The type of loose seton for complex anal fistula is essential to improve perianal comfort and quality of life, *Colorectal Dis.* 18 (6) (2016) O194–O108.
- [201] N. Issa, R. Weil, E. Powsner, W. Khoury, A necktie fashion vascular loop seton tie may simplify the treatment of perianal fistula, *J. Coloproctol.* 37 (1) (2017) 80–85 Rio de Janeiro.
- [202] R. Xu, G. Luo, H. Xia, W. He, J. Zhao, B. Liu, et al., Novel bilayer wound dressing composed of silicone rubber with particular micropores enhanced wound re-epithelialization and contraction, *Biomaterials* 40 (2015) 1–11.
- [203] F.M. RN, An observational study of the use of a soft silicone silver dressing on a variety of wound types, *J. Wound Care* 17 (12) (2008) 535–539.
- [204] V. Patton, C.M. Chen, D. Lubowski, Long-term results of the cutting seton for high anal fistula, *ANZ J. Surg.* 85 (10) (2015) 720–727.
- [205] S.J. Lugowski, D.C. Smith, H. Bonek, J. Lugowski, W. Peters, J. Semple, Analysis of silicon in human tissues with special reference to silicone breast implants, *J. Trace Elem. Med. Biol.* 14 (1) (2000) 31–42.
- [206] J.L. Dziki, L. Huleihel, M.E. Scarritt, S.F. Badylak, Extracellular matrix bioscaffolds as immunomodulatory biomaterials, *Tissue Eng. A.* 23 (19–20) (2017) 1152–1159.
- [207] E.S.A.M.A. Ammar, A.M.A. Lasheen, A.S. Abd-El-Aziz, Cable tie seton in surgical treatment of high perianal fistula, *Egypt. J. Hosp. Med.* 73 (3) (2018) 6304–6309.
- [208] R.S. Killeddar, S. Gupta, P.S. Shindhe, Management of traumatic bilateral ischio rectal abscess (Gudagata Vidradhi) with incision (bhedana) and ksharasutra (medicated seton) technique—a case report, *Ann. Ayurvedic Med.* 7 (1) (2018) 41–44.
- [209] S. Radhakrishna, Multicentric randomized controlled clinical trial of Ksharasootra (Ayurvedic medicated thread) in the management of fistula-in-ano, *Indian J. Med. Res. Sect. B Biomed. Res. Infect. Dis.* 94 (JUN) (1991) 177–185.
- [210] M.B. Gewali, P. Upali, H. Masao, N. Tsunee, Analysis of a thread used in the kshara sutra treatment in the ayurvedic medicinal system, *J. Ethnopharmacol.* 29 (2) (1990) 199–206.
- [211] K. Ho, C. Tsang, F. Seow-Choen, Y. Ho, C. Tang, S. Heah, et al., Prospective randomized trial comparing ayurvedic cutting seton and fistulotomy for low fistula-in-ano, *Tech. Coloproctol.* 5 (3) (2001) 137–141.
- [212] G. Dutta, J. Bain, A.K. Ray, S. Dey, N. Das, B. Das, Comparing ksharasutra (ayurvedic seton) and open fistulotomy in the management of fistula-in-ano, *J. Nat. Sci. Biol. Med.* 6 (2) (2015) 406.
- [213] M. Garcia-Arranz, D. Garcia-Olmo, M.D. Herreros, J. Gracia-Solana, H. Guadaluja, F. De la Portilla, et al., Autologous adipose-derived stem cells for the treatment of complex cryptoglandular perianal fistula: a randomized clinical trial with long-term follow-up, *Stem Cells Transl. Med.* 9 (3) (2020) 295–301.
- [214] J.Z.H. Ko, S. Johnson, M. Dave, Efficacy and safety of mesenchymal stem/stromal cell therapy for inflammatory bowel diseases: an Up-to-Date Systematic review, *Biomolecules* 11 (1) (2021) 82.
- [215] G.E. Salazar-Noratto, G. Luo, C. Denoed, M. Padrona, A. Moya, M. Bensidhoum, et al., Understanding and leveraging cell metabolism to enhance mesenchymal stem cell transplantation survival in tissue engineering and regenerative medicine applications, *Stem Cells* 38 (1) (2020) 22–33.
- [216] B. Zhang, R. Cristescu, D.B. Chrisey, R.J. Narayan, Solvent-based extrusion 3D printing for the fabrication of tissue engineering scaffolds, *Int. J. Bioprint.* 6 (1) (2020) 28–42.
- [217] K. Klimek, G. Ginalska, Proteins and peptides as important modifiers of the polymer scaffolds for tissue engineering applications—a review, *Polymers* 12 (4) (2020) 844.

- [218] J. Kim, H.N. Kim, K.T. Lim, Y. Kim, S. Pandey, P. Garg, et al., Synergistic effects of nanotopography and co-culture with endothelial cells on osteogenesis of mesenchymal stem cells, *Biomaterials* 34 (30) (2013) 7257–7268.
- [219] H. Park, C. Cannizzaro, G. Vunjak-Novakovic, R. Langer, C.A. Vacanti, O.C. Farokhzad, Nanofabrication and microfabrication of functional materials for tissue engineering, *Tissue Eng.* 13 (8) (2007) 1867–1877.
- [220] J.A. Hubbell, Biomaterials in tissue engineering, *Bio Technol.* 13 (6) (1995) 565–576.
- [221] A.I. Caplan, S.P. Bruder, Mesenchymal stem cells: building blocks for molecular medicine in the 21st century, *Trends Mol. Med.* 7 (6) (2001) 259–264.
- [222] J.I. Bleier, H. Moloo, Current management of cryptoglandular fistula-in-ano, *World J. Gastroenterol.* 17 (28) (2011) 3286–3291.
- [223] A. Iqbal, T. Ahmed, I. Khan, S. Perveen, M.I. Khan, Outcome of use of 1% silver nitrate in patients with low lying perianal fistula, *J. Ayub Med. Coll. Abbottabad* 31 (3) (2019) 355–358.
- [224] Y. Zhang, J. Xu, Y. Chai, J. Zhang, Z. Hu, H. Zhou, Nano-silver modified porcine small intestinal submucosa for the treatment of infected partial-thickness burn wounds, *Burns* 45 (4) (2019) 950–956.
- [225] M. Raffi, S. Mehrwan, T.M. Bhatti, J.I. Akhter, A. Hameed, W. Yawar, et al., Investigations into the antibacterial behavior of copper nanoparticles against *Escherichia coli*, *Ann. Microbiol.* 60 (1) (2010) 75–80.
- [226] O. Wiarachai, N. Thongchul, S. Kiattkamjornwong, V.P. Hoven, Surface-quaternized chitosan particles as an alternative and effective organic antibacterial material, *Colloids Surf. B* 92 (2012) 121–129.
- [227] J.J. Blaker, J. Pratten, D. Ready, J.C. Knowles, A. Forbes, R.M. Day, Assessment of antimicrobial microspheres as a prospective novel treatment targeted towards the repair of perianal fistulae, *Aliment. Pharmacol. Ther.* 28 (5) (2008) 614–622.
- [228] F. Paladini, M. Pollini, Antimicrobial silver nanoparticles for wound healing application: progress and future trends, *Materials* 12 (16) (2019) 2540.
- [229] I.X. Yin, J. Zhang, I.S. Zhao, M.L. Mei, Q. Li, C.H. Chu, The antibacterial mechanism of silver nanoparticles and its application in dentistry, *Int. J. Nanomed.* 15 (2020) 2555.
- [230] J.B. Krajewska, O. Dhugosz, M. Sałaga, M. Banach, J. Fichna, Silver nanoparticles based on blackcurrant extract show potent anti-inflammatory effect *in vitro* and in DSS-induced colitis in mice, *Int. J. Pharm.* 585 (2020) 119549.
- [231] S. Zhang, X. Liu, H. Wang, J. Peng, K.K. Wong, Silver nanoparticle-coated suture effectively reduces inflammation and improves mechanical strength at intestinal anastomosis in mice, *J. Pediatr. Surg.* 49 (4) (2014) 606–613.
- [232] M. Maternini, A. Guttadauro, D. Mascagni, G. Milito, A. Stuto, A. Renzi, et al., Non cross-linked equine collagen (Salvecoll-E gel) for treatment of complex ano-rectal fistula, *Asian J. Surg.* 43 (2) (2020) 401–404.
- [233] D.F. Williams, Biocompatibility pathways: biomaterials-induced sterile inflammation, mechanotransduction, and principles of biocompatibility control, *ACS Biomater. Sci. Eng.* 3 (1) (2017) 2–35.
- [234] E.J. Dozois, A.L. Lightner, K.L. Mathis, H.K. Chua, S.R. Kelley, J.G. Fletcher, et al., Early results of a phase I trial using an adipose-derived mesenchymal stem cell-coated fistula plug for the treatment of transsphincteric cryptoglandular fistulas, *Dis. Colon Rectum* 62 (5) (2019) 615–622.
- [235] A.B. Dietz, E.J. Dozois, J.G. Fletcher, G.W. Butler, D. Radel, A.L. Lightner, et al., Autologous mesenchymal stem cells, applied in a bioabsorbable matrix, for treatment of perianal fistulas in patients with Crohn's disease, *Gastroenterology* 153 (1) (2017) 59–62 e2.
- [236] C. Pramudiaty, The study of PLGA drug delivery systems: implications for management of Crohn's disease, *Kaleidoscope* 5 (1) (2015) 11.
- [237] H. Li, B. Jiang, J. Yan, Z. Yang, Y. Chen, W. Zhang, et al., A drug-laden elastomer for surgical treatment of anal fistula, *Drug Deliv. Transl. Res.* 1 (6) (2011) 439–447.
- [238] X. Xie, L. Liu, Z. Zheng, Z. Han, M. Zhi, D.L. Kaplan, et al., Silk fibroin-based fibrous anal fistula plug with drug delivery function, *Macromol. Biosci.* 18 (4) (2018) e1700384.
- [239] L. Zhang, J. Wang, A. Xu, C. Zhong, W. Lu, L. Deng, et al., A rationally designed TNF- $\alpha$  epitope-scaffold immunogen induces sustained antibody response and alleviates collagen-induced arthritis in mice, *PLoS One* 11 (9) (2016) e0163080.
- [240] Y. Zhao, C. Gao, H. Liu, H. Liu, Y. Feng, Z. Li, et al., Infliximab-based self-healing hydrogel composite scaffold enhances stem cell survival, engraftment, and function in rheumatoid arthritis treatment, *Acta Biomater.* 121 (2020) 653–664.
- [241] Y. Zhao, C. Gao, H. Liu, H. Liu, Y. Feng, Z. Li, et al., Infliximab-based self-healing hydrogel composite scaffold enhances stem cell survival, engraftment, and function in rheumatoid arthritis treatment, *Acta Biomater.* 121 (2021) 653–664.
- [242] S. Mantha, S. Pillai, P. Khayambashi, A. Upadhyay, Y. Zhang, O. Tao, et al., Smart hydrogels in tissue engineering and regenerative medicine, *Materials* 12 (20) (2019) 3323.
- [243] K. Zhang, S. Wang, C. Zhou, L. Cheng, X. Gao, X. Xie, et al., Advanced smart biomaterials and constructs for hard tissue engineering and regeneration, *Bone Res.* 6 (1) (2018) 1–15.
- [244] Q. Mao, O. Hoffmann, K. Yu, F. Lu, G. Lan, F. Dai, et al., Self-contracting oxidized starch/gelatin hydrogel for noninvasive wound closure and wound healing, *Mater. Des.* 194 (2020) 108916.
- [245] X. Zhao, H. Wu, B. Guo, R. Dong, Y. Qiu, P.X. Ma, Antibacterial anti-oxidant electroactive injectable hydrogel as self-healing wound dressing with hemostasis and adhesiveness for cutaneous wound healing, *Biomaterials* 122 (2017) 34–47.
- [246] G. Li, Y. Wang, S. Wang, Z. Liu, Z. Liu, J. Jiang, A thermo-and moisture-responsive zwitterionic shape memory polymer for novel self-healable wound dressing applications, *Macromol. Mater. Eng.* 304 (3) (2019) 1800603.
- [247] F. Zhang, Y. Xia, Y. Liu, J. Leng, Nano/microstructures of shape memory polymers: from materials to applications, *Nanoscale Horiz.* 5 (8) (2020) 1155–1173.
- [248] S.Y. Nam, S.H. Park, ECM based bioink for tissue mimetic 3D bioprinting, *Adv. Exp. Med. Biol.* 1064 (2018) 335–353.
- [249] J.J. Norman, T.A. Desai, Methods for fabrication of nanoscale topography for tissue engineering scaffolds, *Ann. Biomed. Eng.* 34 (1) (2006) 89–101.
- [250] R. Lanza, R. Langer, J.P. Vacanti, A. Atala, Principles of Tissue Engineering, Academic Press, 2020.
- [251] A. Khademhosseini, R. Langer, J. Borenstein, J.P. Vacanti, Microscale technologies for tissue engineering and biology, *Proc. Natl. Acad. Sci.* 103 (8) (2006) 2480–2487.
- [252] A.L. Lightner, E.J. Dozois, A.B. Dietz, J.G. Fletcher, J. Fritton, G. Butler, et al., Matrix-delivered autologous mesenchymal stem cell therapy for refractory rectovaginal Crohn's fistulas, *Inflamm. Bowel Dis.* 26 (5) (2020) 670–677.
- [253] S. Aggarwal, M.F. Pittenger, Human mesenchymal stem cells modulate allogeneic immune cell responses, *Blood* 105 (4) (2005) 1815–1822.
- [254] J. Panes, D. Garcia-Olmo, G. Van Assche, J.F. Colombel, W. Reinisch, D.C. Baumgart, et al., Expanded allogeneic adipose-derived mesenchymal stem cells (Cx601) for complex perianal fistulas in Crohn's disease: a phase 3 randomised, double-blind controlled trial, *Lancet* 388 (10051) (2016) 1281–1290.
- [255] J. Panes, D. Garcia-Olmo, G. Van Assche, J.F. Colombel, W. Reinisch, D.C. Baumgart, et al., Long-term efficacy and safety of stem cell therapy (Cx601) for complex perianal fistulas in patients with Crohn's disease, *Gastroenterology* 154 (5) (2018) 1334–1342 e4.
- [256] C. Philandrianos, M. Serrero, F. Grimaud, J. Magalon, C. Visee, M. Velier, et al., First clinical case report of local microinjection of autologous fat and adipose-derived stromal vascular fraction for perianal fistula in Crohn's disease, *Stem Cell Res. Ther.* 9 (1) (2018) 4.
- [257] C. Wainstein, R. Quera, D. Fluxa, U. Kronberg, A. Conejero, F. Lopez-Kostner, et al., Stem cell therapy in refractory perineal Crohn's disease: long-term follow-up, *Colorectal Dis.* 20 (2018) 68–75.
- [258] P. Szymczyk-Ziółkowska, M.B. Łabowska, J. Detyna, I. Michalak, P. Gruber, A review of fabrication polymer scaffolds for biomedical applications using additive manufacturing techniques, *Biocybern. Biomed. Eng.* 40 (2) (2020) 624–638.
- [259] H. Khalil, F. Jummaat, E.B. Yahya, N. Olaiya, A. Adnan, M. Abdat, et al., A review on micro-to nanocellulose biopolymer scaffold forming for tissue engineering applications, *Polymers* 12 (9) (2020) 2043.
- [260] T.J. Al-Marzooq, Q.A. Hassan, M.K. Alnaser, Al-Edani MS, Treatment of fistula-in-ano with tight (Cutting) seton: analysis of outcomes and efficacy assessment, *J. Clin. Diagn. Res.* 11 (11) (2017).
- [261] M. Jang, S. Bae, Y. Jung, J. Kim, J. Kim, S. Park, et al., Enhanced wound healing using a 3D printed VEGF-mimicking peptide incorporated hydrogel patch in a pig model, *Biomed. Mater.* 16 (4) (2021) 045013.
- [262] K. Da Silva, P. Kumar, Y.E. Choonara, L.C. du Toit, V. Pillay, Three-dimensional printing of extracellular matrix (ECM)-mimicking scaffolds: a critical review of the current ECM materials, *J. Biomed. Mater. Res.* A 108 (12) (2020) 2324–2350.
- [263] C.J. Kowalczewski, J.M. Saul, Biomaterials for the delivery of growth factors and other therapeutic agents in tissue engineering approaches to bone regeneration, *Front. Pharmacol.* 9 (2018) 513.
- [264] K. Ye, H. Kuang, Z. You, Y. Morsi, X. Mo, Electrospun nanofibers for tissue engineering with drug loading and release, *Pharmaceutics* 11 (4) (2019) 182.
- [265] D.K. Ocansey, L. Zhang, Y. Wang, Y. Yan, H. Qian, X. Zhang, et al., Exosome-mediated effects and applications in inflammatory bowel disease, *Biol. Rev.* 95 (5) (2020) 1287–1307.
- [266] Y. Cao, Q. Su, B. Zhang, F. Shen, S. Li, Efficacy of stem cells therapy for Crohn's fistula: a meta-analysis and systematic review, *Stem Cell Res. Ther.* 12 (1) (2021) 1–11.
- [267] Z. Jiang, G. Liu, F. Meng, W. Wang, P. Hao, Y. Xiang, et al., Paracrine effects of mesenchymal stem cells on the activation of keratocytes, *Br. J. Ophthalmol.* 101 (11) (2017) 1583–1590.
- [268] M.G. Mohamed, P. Ambhorkar, R. Samanipour, A. Yang, A. Ghafoor, K. Kim, Microfluidics-based fabrication of cell-laden microgels, *Biomicrofluidics* 14 (2) (2020) 021501.